

## T1(Gd) of Meniscus in dGEMRIC scans: An Index of Meniscal Tissue Degeneration?

N. Krishnan<sup>1</sup>, A. Williams<sup>1</sup>, B. Mikulis<sup>1</sup>, C. McKenzie<sup>1,2</sup>, and D. Burstein<sup>1,3</sup>

<sup>1</sup>Radiology, Beth Israel Deaconess Medical Center, Boston, Massachusetts, United States, <sup>2</sup>Radiology, Harvard Medical School, Boston, Massachusetts, United States, <sup>3</sup>Health Sciences and Technology, MIT, Boston, Massachusetts, United States

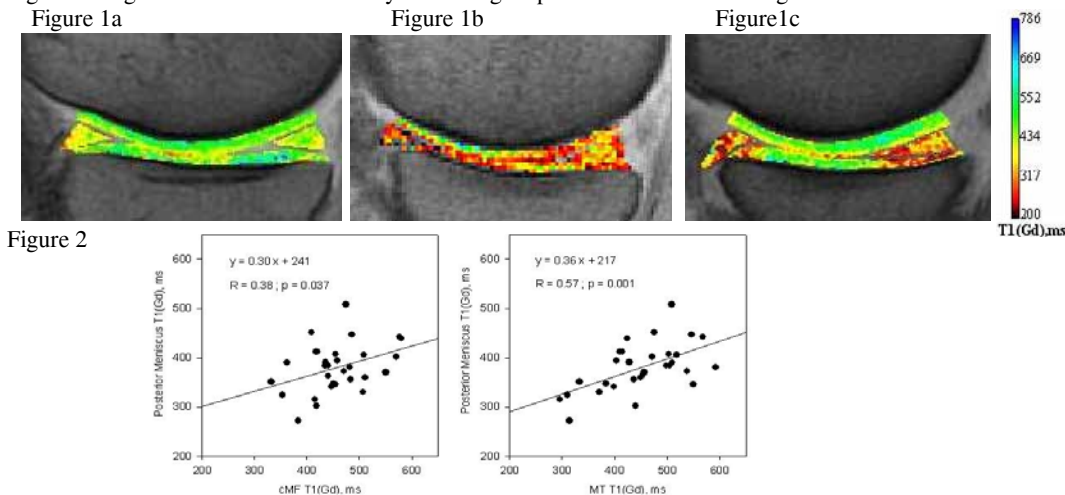
**Purpose:** Much attention has been focused lately on the need for better understanding the pathogenesis and natural progression of knee osteoarthritis (OA), particularly in its earlier stages. One such technique utilized in this regard is dGEMRIC (delayed Gadolinium Enhanced MRI of Cartilage). In clinical studies, the dGEMRIC Index of articular cartilage, reported as T1(Gd) (T1 after penetration of Gd-DTPA<sup>2-</sup>), has been shown to correlate with a number of physiologic and clinical findings (1). The meniscus, a crucial load-attenuating fibrocartilage of the knee, has been associated with knee OA (2). However, its highly structured matrix results in a very fast T2 MRI relaxation time, and hence has not been well visualized in dGEMRIC scans. The recent development of fast Spoiled Gradient Echo (fSPGR) 3D T1 mapping pulse sequences for dGEMRIC (3,4) has resulted in echo times under 3.0 millisecond, allowing for calculation of T1(Gd) of the meniscus. The aim of this study was to examine the T1 (Gd) of meniscus tissue of the knee and its relationship to articular cartilage T1(Gd).

**Methods:** dGEMRIC scans of 30 individuals were analyzed. Two ROIs were segmented in cartilage: one containing the central femoral cartilage (cMF, cLF in medial and lateral condyles respectively) and another containing the tibial cartilage (MT, LT in medial and lateral condyles respectively). For meniscus: two ROIs, one containing the posterior meniscus and the other containing the anterior meniscus in each of the medial and lateral sagittal sections were drawn. T1 (Gd) maps were then generated. The T1 (Gd) data were corrected for dose bias (5).

**Results:** The T1(Gd) of femoral and tibial cartilages ranged from 296 to 616 ms. The T1(Gd) range for meniscus was 247 to 515 ms. A range of T1(Gd) values and patterns were seen in meniscus in this study (Figure 1). Low values in the menisci sometimes matched "lesions" in an adjacent region of articular cartilage as seen in Figure 1c. Positive correlation was found between articular cartilage cMF (and MT) and posterior meniscus in the medial section with  $R = 0.38$ ,  $p = 0.037$  ( $R = 0.57$ ,  $p = 0.001$  for MT) as seen in Figure 2. Similar trends were also seen laterally between cartilage and meniscus.

**Discussion:** The positive correlation between T1 (Gd) of cartilage and meniscus may indicate parallel degradative processes occurring in both tissues. The interpretation of T1(Gd) in the meniscus is not yet clear. The distribution of Gd-DTPA<sup>2-</sup> in meniscus may not be dominated by GAG distribution; other influencing factors could be increased steric hindrance by the collagen matrix of the meniscus, and/or transport of Gd-DTPA<sup>2-</sup> into the tissue. In addition, the relaxivity of contrast agents in meniscus is not well studied. These factors require further investigation. Nevertheless, a means of monitoring molecular changes in the meniscus under clinical conditions, and their correlation to cartilage molecular changes, may yield important insights into the development and progression of knee OA.

Figure 1: Sagittal views of medial condyle showing maps across articular cartilage and meniscus.



### References

1. Burstein D. MRI for development of disease-modifying osteoarthritis drugs. *NMR Biomed* 2006;19(6):669-680.
2. Hunter DJ, Zhang YQ, Niu JB, Tu X, Amin S, Clancy M, Guermazi A, Grigorian M, Gale D, Felson DT. The association of meniscal pathologic changes with cartilage loss in symptomatic knee osteoarthritis. *Arthritis Rheum* 2006;54(3):795-801.
3. McKenzie CA, Williams A, Prasad PV, Burstein D. Three-dimensional delayed gadolinium-enhanced MRI of cartilage (dGEMRIC) at 1.5T and 3.0T. *J Magn Reson Imaging* 2006;24(4):928-933.
4. Kimelman T, Vu A, Storey P, McKenzie C, Burstein D, Prasad P. Three-dimensional T1 mapping for dGEMRIC at 3.0 T using the Look Locker method. *Invest Radiol* 2006;41(2):198-203.
5. Tiderius C, Hori M, Williams A, Sharma L, Prasad PV, Finnell M, McKenzie C, Burstein D. dGEMRIC as a function of BMI. *Osteoarthritis Cartilage* 2006;14(11):1091-1097.