

# Soluble telencephalin is a marker for frontotemporal dysfunction in epilepsy as revealed by fMRI

J. F. Jansen<sup>1</sup>, M. C. Vlooswijk<sup>2</sup>, M. H. de Baets<sup>2</sup>, P. Rieckmann<sup>3</sup>, M. E. Kooi<sup>1</sup>, A. P. Aldenkamp<sup>4</sup>, H. M. Majoie<sup>4</sup>, R. P. Reijts<sup>4</sup>, M. C. de Krom<sup>2</sup>, P. A. Hofman<sup>1</sup>, K. Nicolay<sup>5</sup>, and W. H. Backes<sup>1</sup>

<sup>1</sup>Department of Radiology, Maastricht University Hospital, Maastricht, Netherlands, <sup>2</sup>Department of Neurology, Maastricht University Hospital, Maastricht, Netherlands, <sup>3</sup>Department of Neurology, Julius-Maximilians University Hospital, Wuerzburg, Germany, <sup>4</sup>Epilepsy Centre Kempenhaeghe, Heeze, Netherlands, <sup>5</sup>Biomedical NMR, Department of Biomedical Engineering, Eindhoven University of Technology, Eindhoven, Netherlands

## Introduction

Soluble telencephalin (intercellular adhesion molecule 5 (ICAM-5)) is a neuronal glycoprotein. Increased concentrations of soluble telencephalin in serum and cerebrospinal fluid have been reported in temporal lobe epilepsy and acute herpes simplex encephalitis [1]. Telencephalin has been suggested as a marker for neuronal damage [2].

Functional MRI (fMRI) enables the localization of brain activation by demonstrating a blood oxygenation level dependent (BOLD) signal during a (cognitive) paradigm. With fMRI, possible alterations in the functional neuroanatomy of working memory can be visualized using the Sternberg paradigm, a choice reaction time test reflecting verbal working memory performance [3]. Previous studies have demonstrated prefrontal and temporal activation using this paradigm [4].

Temporal cortex dysfunction, which has been reported in localization-related epilepsy, can be demonstrated by decreased local activation with fMRI [5]. We investigated cortical dysfunction in adult patients with localization-related epilepsy and secondarily generalized seizures.

## Material and Methods

We included 16 patients with a frontal seizure focus (n=5), temporal seizure focus (n=10) and one patient with unknown seizure focus. Both temporal and frontal seizure focus were included, since frontal seizures tend to generalize rapidly [6], and both seizure types are known to spread. Etiology varied from symptomatic (mesiotemporal sclerosis, arachnoid cyst, cortical dysplasia, anti-phospholipid-syndrome; n=8) to cryptogenic (n=8). To detect soluble telencephalin in serum, a sensitive sandwich immunoassay with two mouse monoclonal antibodies to the extracellular domains of human telencephalin was used [1]. fMRI-data were acquired on a 1.5-Tesla unit (Philips Medical Systems, The Netherlands) using a whole-cerebrum single-shot three-dimensional BOLD echo-planar imaging sequence. During fMRI, patients performed a covert Sternberg test in which subjects were asked to memorize visually presented letters. Subjects then indicated by pressing a button whether or not single displayed letters were in the memory set. The paradigm consisted of 16 blocks (memory set for four seconds followed by 13 response letters of two seconds each) alternating with 16 baseline rest condition blocks (30 s each, subjects were asked to focus on a crosshair). The memory set varied from one to four letters, presented in a random fashion with a total of four blocks for each load.

fMRI data analysis was performed in SPM2 (Wellcome Department of Cognitive Neurology, UK) and was focused on five volumes of interest covering the temporal and prefrontal cortex. The volumes of interest were the prefrontal area (i.e. superior prefrontal cortex), frontotemporal area (i.e. peri-insular cortex), anterior cingulate cortex, Broca's and Wernicke's areas. The frontotemporal area comprised the insula extending to the superior temporal and inferior frontal cortex. Activation maps were calculated for the contrast between all loads and the resting condition. The relative activation level in the volumes of interest was expressed as the fraction of the 5,000 most active voxels (approximately 1% of the cerebrum) from the temporal and prefrontal cortex.

## Results

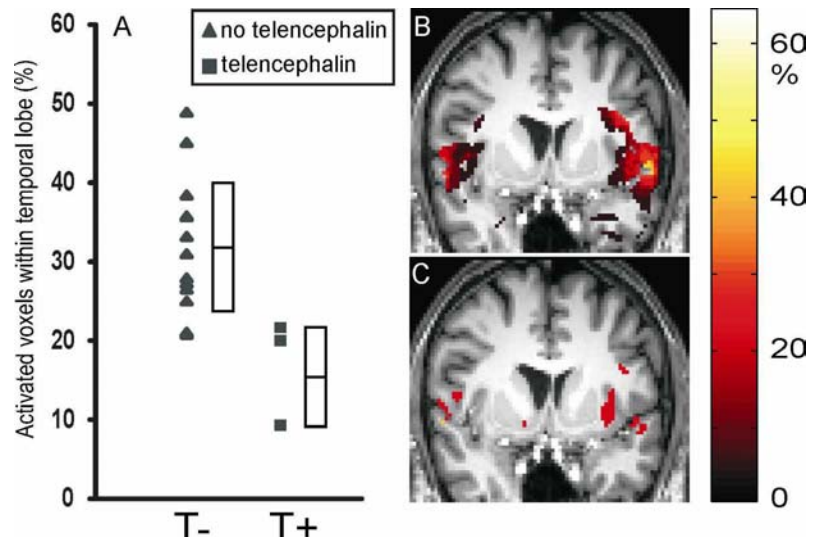
In three patients, one with temporal lobe and two with frontal lobe epilepsy, telencephalin was detected (2.1, 8.4, and 36.5 ng/mL). All three individuals had lower BOLD-signals in the frontotemporal region ( $p=0.015$ , Mann-Whitney-U), but not in the other regions ( $p>0.35$ ) compared to patients without detectable telencephalin (Figure 1). No differences were found in etiology (symptomatic or cryptogenic) between groups ( $p>0.1$ ).

## Discussion

Previous data suggested that the appearance of soluble telencephalin in serum due to changes in cerebral telencephalin expression can be induced by both acute and chronic neurodegenerative conditions such as encephalitis [7] and temporal lobe epilepsy [1], respectively. In the current study, patients with localization-related epilepsy of both temporal and extratemporal origin were selected to investigate the consequences of this chronic condition on cortical function. To our knowledge, this is the first study that demonstrates an association between a decreased frontotemporal activation on fMRI and detectable telencephalin serum levels. Despite the limited number of patients, our results suggest that increased telencephalin levels are not a direct consequence of a temporal seizure focus, since detectable levels were found in frontal lobe epilepsy as well. Possibly, it reflects frontotemporal damage due to spread of seizures of both temporal and extratemporal origin. We hypothesize that frontotemporal dysfunction in localization-related epilepsy might be better predicted by the promising biochemical marker telencephalin than seizure focus.

## References

- [1] Rieckmann P, et al. *Lancet* 1998;352:370-371.
- [2] Guo H, et al. *Ann Neurol* 2000;48:590-602.
- [3] Manoach DS, et al. *Neuroreport* 1997;8:545-549.
- [4] Hillary FG, et al. *J Clin Exp Neuropsychol* 2003;25:965-978.
- [5] Cheung MC, et al. *Epilepsia* 2006;47:1320-1328.
- [6] Niedermeyer E. *Clin Electroencephalogr* 1998;29:163-169.
- [7] Lindsberg PJ, et al. *Neurology* 2002;58:446-451.



**Figure 1**

A) Relative activation of the frontotemporal cortex for the non-telencephalin group (T-; left) and telencephalin group (T+; right). Boxes show mean  $\pm$  SD. B-C) Coronal images of fMRI activation maps obtained for the Sternberg paradigm overlaid on a spatially normalized T1-weighted MR image, for the non-telencephalin group (B) and telencephalin group (C). Activation maps show percentage of patients in which a region is activated. Slice positions are  $y=+8$  mm in stereotactic Talairach coordinates.