

The pattern of brain iron accumulation during normal aging

X. Xu¹, M. Zhang¹, Q. Wang¹, and F. Sun²

¹Radiology, First Affiliated Hospital, School of Medicine, Zhejiang University, Hangzhou, China, People's Republic of, ²GE Healthcare China

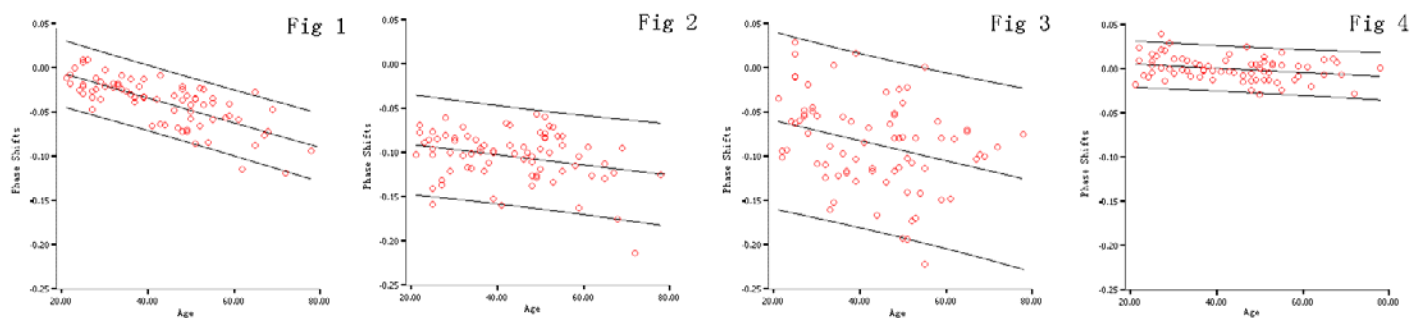
Introduction

Accumulations of iron in the basal ganglia were frequently observed in neural disorders, such as Parkinson's disease, Alzheimer disease and Huntington's disease [1]. But the extent of iron accumulation in the progression of most degenerative diseases has been unclear, in part because iron accumulation occurred in all normal human brain. Therefore, to know the iron accumulation in the basal ganglia with aging should be important for understanding disease-related iron deposition. Due to the fact that higher iron content will leads to a greater negative phase relative to the surrounding parenchyma, phase images of GRE sequence are sensitive to detect minor iron concentration differences in the brain [2]. In this study, we utilized phase image to measure brain iron level in vivo and tried to find the pattern of brain iron accumulation during normal aging.

Materials and Methods

Seventy-seven healthy adult volunteers were studied with a GE 1.5T Signa EXCITE II scanner. The subjects ranged in age from 21 to 78 years (mean=43.9, SD=13.9). All the subjects were imaged with the following 3D GRE sequence: TR=51ms, TE=38ms, FA=20°, slice thickness = 2mm, FOV = 24cm, and matrix size = 256×256. The slab contained 28 continuous slices, and the slab center was superposed on the anterior and posterior commissure line (AC-PC line). A spatial high-pass filter was applied to the initial phase image to remove slowly varying phase shifts caused by background static field gradients. The phase shifts were measured on the "corrected" phase images in six subcortical structures. The third and fourth slices above the AC-PC line were used to obtain the data of the globus pallidus (GP), putamen (PU), caudate (CA), thalamus (TH) and frontal white matter (FWM), and the second and third slice inferior to the AC-PC line were used to obtain the data of the substantia nigra (SN) and red nucleus (RN). All the data were obtained from contiguous pairs of slice. In each region, linear regression analysis was used to explore the relationship between age and the phase shifts.

Results



Age-related phase decrease was observed in PU ($R^2=0.534$, $P<0.001$) (Fig 1), CA ($R^2=0.079$, $P=0.014$) (Fig 2), RN ($R^2=0.095$, $P=0.006$) (Fig 3), and FWM ($R^2=0.065$, $P=0.0$) (Fig 4), which indicated brain iron accumulation during normal aging in these regions. No significant age-related phase changes were detected in GP ($R^2=0.013$, $P=0.330$), SN ($R^2=0.014$, $P=0.312$), and TH ($R^2=0.004$, $P=0.588$).

Discussion

Age-related iron deposition occurred in some subcortical regions and the frontal white matter, while no further iron increase occurred in GP and SN in normal adults. These findings were consistent with a classic postmortem study [3]. Since measuring the amount of iron deposits in the brain may provide new biomarkers of neurodegenerative diseases, the pattern of the accumulation of iron in the basal ganglia with aging found in this study could be a baseline to understand disease-related changes that involve iron deposition.

Reference

- [1]. Thomas M, Jankovic J. *Curr Opin Neurol* 2004; 17: 437-422.
- [2]. Abduljalil AM, Schmalbrock P, Novak V, et al. *J Magn Reson Imaging* 2003; 18: 284-290.
- [3]. Hallgren B, Sourander P. *J Neurochem* 1958; 3: 41-51.

Supported by NSFC (30570536)