

Identification of a multivariate biomarker of Alzheimer's disease with ASL

C. Habeck¹, I. Asllani¹, A. Borogovac¹, N. Scarmeas¹, T. Brown¹, and Y. Stern¹

¹Columbia University, New York, New York, United States

Introduction

Functional networks operate in the brain and have been observed during the performance of cognitive tasks through a variety of different analytic approaches utilizing interregional correlation of activation. An interesting question is whether functional networks can be observed at rest, and whether there are disease-related changes in network operation that could serve as a means of early disease detection, prior to the obvious onset of focal deficits that are usually targeted with univariate analysis. Principal components analysis (PCA) has a history of successful applications of diagnostic H₂¹⁵O- and FDG-PET patterns in Parkinson's disease (e.g. [3]) and even in normal aging [1,2]. We want to build on our and other groups' successful usage of PCA and apply it to Alzheimer's disease (AD). Further, we want to investigate the suitability of Arterial Spin Labeling (ASL), a relatively new, cheap and non-invasive scanning modality that uses water as an endogenous tracer of cerebral blood-flow. Combining multivariate analysis with the ease of ASL scanning could provide a simple and quick, yet powerful, way of quantifying disease-related changes with one single 'neural network score', enabling early AD diagnosis when clear functional and clinical deficits have not been established yet.

Methods

Eleven early Alzheimer's disease (AD) subjects, and 21 healthy elderly control subjects were scanned with ASL at rest. Informed consent, as approved by the Internal Review Board of the College of Physicians and Surgeons of Columbia University, was obtained prior to study participation for all subjects. All imaging was performed in a 1.5T Philips Intera scanner (Philips Medical Systems, Best, Netherlands) using a standard transmit-receive head coil. Single shot spin-echo EPI CASL perfusion images were acquired with the following parameters: TR/TE/FA = 4s/36ms/90°; 15 slices; FOV=220 × 198 mm; matrix 64 × 51; slice thickness/gap = 8mm/1mm; post-label delay = 800ms; labeling time = 2.0s. For all the subjects the labeling plane was positioned 100 mm proximal to the center of the imaging volume. In addition, high resolution, T1-weighted, 3D SPGR images (TE/TR/FA = 3 ms/34 ms/45°; 100 slices; slice thickness/gap = 1.5mm/1mm; FOV = 240 × 240 mm; matrix = 256 × 256) were acquired. These images were used for the computerized anatomical alignment of the brains of different subjects for 3D image analysis

Multivariate analysis

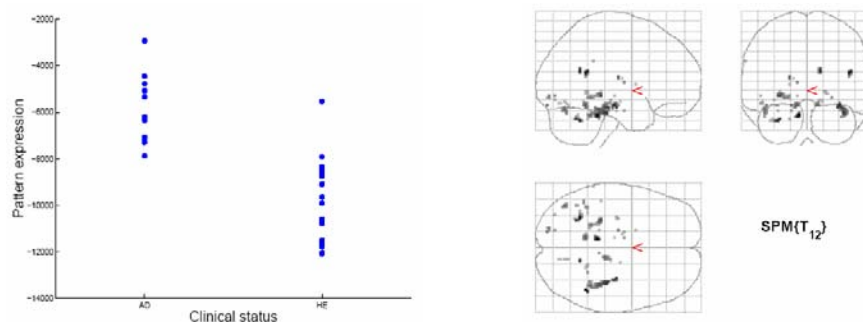
The scans from both AD subjects and controls were subjected to PCA. The subject-expression values of the first 4 principal-component patterns were entered as independent variables in a linear regression that predicted subjects' clinical dementia rating scale (CDR; 1 for subjects, 0 for controls). The best-fit weights from this linear regression were used to construct a flow pattern that maximally discriminated between patients and controls. For the estimation of the robustness of regional loadings in this covariance pattern, a bootstrap estimation procedure was performed that sampled from the two groups with replacement 500 times, each time performing a PCA with subsequent discriminant analysis using 4 principal components, similarly to the derivation of the point estimate. The ratio of the point-estimate value of a regional loading and the standard deviation computed from the bootstrap samples can be interpreted as a z-statistic. Regions with |z|>2 were interpreted as reliable contributors to the discriminant pattern.

Results

A pattern could be derived whose subject expression discriminated significantly between patients and controls (p<0.01). The ROC curve for the discrimination was 0.96. The bootstrap estimation procedure produced a cluster of areas that showed decreased blood flow for the AD subjects in the following locations: right superior temporal gyrus (BA 13), right posterior cingulate gyrus (BA 31), bilateral parahippocampal gyrus (BA 19,36,37), right fusiform gyrus (BA 20,37), left hippocampus, left fusiform gyrus (BA 19), bilateral thalamus. These areas show decreases in flow that are regionally correlated across subjects and therefore were detected by our multivariate analytic technique. Univariate analysis, on the other hand, failed to show any regional differences between patients and controls at a p-level of p<0.001.

Left: subject expression of the discriminant pattern for both AD subjects ('AD') and healthy elderly control ('HE'). One can appreciate the very small overlap between the two groups.

Right: areas with robust negative loadings as ascertained by the bootstrap procedure, i.e. showing decreased flow for the AD subjects relative to controls. Most areas are located around the parahippocampal gyrus in the medial temporal and occipital lobe. The thalamus was identified by our analysis too. No areas of positive loadings (= increased flow for AD subjects) were found.



Discussion

Multivariate analysis of regional cerebral blood flow acquired with ASL shows great promise to provide a sensitive biomarker for the early detection of Alzheimer's disease. A covariance pattern could be derived that discriminated between early AD subjects and healthy elderly controls with good ROC characteristics, while a univariate comparison failed to identify focal disease-related differences at p<0.001. The next steps for the validation of the multivariate approach will be the prospective application with a diagnostic and prognostic test of the AD-related pattern in a replication sample. Further, we plan to combine the AD-related patterns with other disease markers such as neuropsychological test performance and hippocampal volume to derive a disease 'score' with even better ROC characteristics.

References

- [1] Alexander, G.E., Chen, K., Merkle, T.L., Reiman, E.M., Caselli, R.J., Aschenbrenner, M., Santerre-Lemmon, L., Lewis, D.J., Pietrini, P., Teipel, S.J., Hampel, H., Rapoport, S.I. and Moeller, J.R., Regional network of magnetic resonance imaging gray matter volume in healthy aging, *Neuroreport*, 17 (2006) 951-6.
- [2] Brickman, A.M., Habeck, C., Zarahn, E., Flynn, J. and Stern, Y., Structural MRI covariance patterns associated with normal aging and neuropsychological functioning, *Neurobiol Aging* (2006).
- [3] Eidelberg, D., Moeller, J.R., Dhawan, V., Sidtis, J.J., Ginos, J.Z., Strother, S.C., Cedarbaum, J., Greene, P., Fahn, S. and Rottenberg, D.A., The metabolic anatomy of Parkinson's disease: complementary [18F]fluorodeoxyglucose and [18F]fluorodopa positron emission tomographic studies, *Mov Disord*, 5 (1990) 203-13.