

Direction-sensitive perfusion with q-space MRI: phantom validation and calf-muscle probing

D. C. Karampinos^{1,2}, K. F. King³, and J. G. Georgiadis^{1,2}

¹Mechanical Science and Engineering Dept., University of Illinois at Urbana-Champaign, Urbana, IL, United States, ²Beckman Institute for Advanced Science and Technology, University of Illinois at Urbana-Champaign, Urbana, IL, United States, ³GE Healthcare, Waukesha, WI, United States

Introduction: Model-based q-space methodologies based on the intravoxel incoherent motion (IVIM) technique [1], have been extensively used to quantify the microcirculation, but their application has been mainly hindered by their low sensitivity and their high SNR requirements. However, an important advantage of these techniques, which has not been sufficiently explored, is the directional sensitivity they afford when applied in tissues with anisotropic microcirculation as in the myocardium [2]. Here, we revisit the methodology developed by LeBihan [1] and take into account the directional sensitivity of the signal when the technique is judiciously implemented with an appropriate tissue, like large skeletal muscles. The calf muscles constitute an excellent perfusion model for the development of quantitative perfusion-weighted MRI techniques [3], have microcirculatory flow of sufficiently preferential direction within many MRI voxels, and their problem is of clinical importance in assessing the impairment of the microcirculation, such as in diabetes and peripheral vascular disease.

Theory: Inspired by [1] and extending [4], an analytical description of the echo attenuation signal is derived by considering that the MR signal within each voxel is the sum of an intravascular component (transport due to flow and diffusion) and an extravascular component (transport due to diffusion). The two compartments are not interacting, so the echo attenuation is given by a signal-weighted average of intra- and extravascular terms, assuming a microvascular morphology. For blood flow (self-diffusion coefficient D_{in}) with a mean velocity \bar{u} through a population of parallel capillaries with the same radius α , for a diffusion time Δ at the long time scale limit ($\Delta \gg \alpha^2/D_{in}$), and by limiting q so that microcirculation flow effects are not drastically attenuated ($q \bar{u} \Delta \sim 1$), the intravascular echo attenuation, when q is applied parallel to the direction of the flow, can be obtained in an analytical form:

$$E_{in}(q, \Delta) = \exp(-4\pi^2 q^2 D_{eff} \Delta) \exp(j2\pi q \bar{u} \Delta) \text{ where } D_{eff} = D_{in} + \frac{(\bar{u}\alpha)^2}{48\Delta}$$

Results: A perfusion phantom was constructed using 0.86 mm inner diameter plastic tubing, wrapped 10 times around a curved plastic plate with a distance between the tubing segments of ~8 mm and immersed in a water bath (Fig. 1a). A syringe pump imposes steady flow velocity in the range 3-5 mm/sec. A 30-direction, 6 gradient amplitudes, q-space EPI sequence was implemented on a 3 T GE scanner with the following parameters: FOV= 20x20 cm, 4.5 mm slice thickness, 64x64 matrix size, 8-shots, TR/TE=1000/100 ms, $\delta=10$ ms, $\Delta=50$ ms and $g \leq 1.75$ G/cm. This resolution (Fig. 1b) corresponds to a 4 % volume fraction of intratubular volume, which agrees with typical intravascular volume fraction values. The solution of the inverse problem, gives the tube orientation (Fig. 1c), the extravascular diffusion coefficient and the intravascular volume in every voxel. The phantom velocity results agreed within 10% of the theoretical values. For the human scans, we modified the procedure to conform with in-vivo imaging constraints (hemodynamic time scales and involuntary motion) using the following protocol. The volunteer lied supine with one leg inserted in a lower extremity RF coil at the calf level (Fig. 2a) and an air-cuff was applied above the knee. The sequence consisted of a series of 30 interleaved acquisitions each spanning four b-values with the diffusion gradient applied along the axis parallel to the muscle fibers (Fig. 2b). Scans were taken before cuff inflation (baseline), 4 min after the cuff was inflated to 200 mm Hg (ischemia), and 1 min after the cuff deflation (reactive hyperemia). The time-averaged normalized echo attenuation for high q-values depends only on the extravascular contribution and reflects the expected trend in the change of the extravascular component contribution. The normalized signal increases during ischemia and decreases during hyperemia (cf. [5]). The effect of perfusion can, in principle, be extracted from the normalized low q-value echo attenuation, but more work is needed to determine if a quantitatively correct extraction is possible. Qualitative consistency of the data, however, indicates that such an approach is worth pursuing.

Conclusion: The normalized echo attenuation for the physiological case is consistent with the expected relative contribution of local perfusion to the total signal as the microcirculation of the calf muscle transitions from the baseline, to the ischemic, and then to hyperemic state. Further work will determine if quantitative assessment of local perfusion is possible with this methodology.

References: [1] LeBihan, D. *Diffusion and Perfusion Magnetic Resonance Imaging* (New York, 1995). [2] Callot V *et al. Magn. Res. Med.* **50**, 531-540 (2003). [3] Lutz M *et al. J. Magn. Res. Imag.* **20**, 111-121 (2004). [4] Raguin LG *et al. Proc. ISMRM 2006*, Seattle. [5] Chenevert TL *et al. Magn. Res. Med.* **17**, 197-212 (1991).

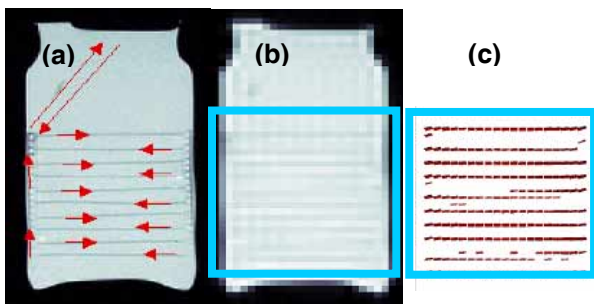


Figure 1. MRI perfusion phantom experiment. (a) spin-echo image, (b) q=0 spin-echo EPI image, (c) tubing reconstruction.

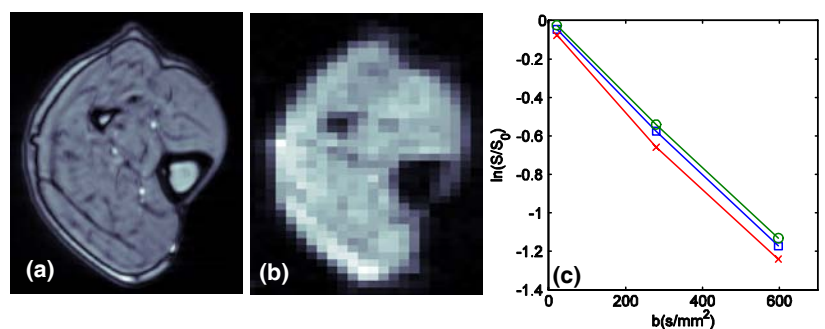


Figure 2. MRI calf muscle experiment. (a) anatomical and (b) 64x64 q=0 image and (c) plot of normalized signal attenuation in a 5x5 voxels ROI centered in the gastrocnemius muscle for the 3 conditions: baseline (square symbol), ischemia (round symbol), hyperemia (plus symbol).