

MRI-monitoring of hyperthermia induced Gadodiamide release from long-circulating thermosensitive liposomes in tumors

M. Peller¹, A. Schwerdt², M. Hossann³, H. M. Reinl¹, R. D. Issels^{3,4}, L. Lindner^{3,4}, and M. Reiser¹

¹Department of Clinical Radiology, University Hospital of Munich, Munich, Germany, ²Pharmaceutical Biology-Biotechnology, Department for Pharmacy, University of Munich, Germany, ³Department of Medicine III, University Hospital of Munich, Germany, ⁴Institute for Molecular Immunology, KKG "Hyperthermia"/GSF-Natl. Research Center for Environment and Health, Germany

Introduction: Hyperthermia has proven to be an effective treatment concept for locally advanced deep-seated tumors (1,2). The use of thermosensitive liposomes (TSL) with either encapsulated Gd³⁺ or Mn²⁺ for MR thermometry and drug release has been proposed for therapy monitoring. This is based on the thermotropic polymorphism of the liposomes. The paramagnetic compounds are released at the phase transition temperature of TSL and act as T1-shortening MR contrast agent (3,4,5). Recently, a novel formulation for long-circulating TSL (LTSL) has been successfully developed with a phase transition temperature of 42°C, which is consistent with the therapeutical hyperthermia temperature level for tumors combined with chemotherapy (6).

Purpose of this study was to investigate the dynamics of temperature induced contrast agent release from new long-circulating thermosensitive liposomes with encapsulated Gd-DTPA-BMA (Gd-LTSL) in presence of tumor perfusion in a clinical applicable MRI system.

Material and Methods: Four C57Bl/6 mice (body weight: 29±1g) with BFS-1 fibrosarcoma (mean tumor volume: 329±71 mm³) at the hind leg were studied 2 weeks after tumor inoculation. The mice were anesthetized intraperitoneal (i.p.) with a solution of Ketamine (@Ketavet, Pharmacia, Germany), 0.9% NaCl solution and Xylazin (@Rompun 2%, Bayer, Germany). The tumor bearing leg was submerged into a temperature controlled water bath containing 0.5 g/l MnCl₂ water. Body temperature was monitored using a fiberoptic temperature probe placed in the rectum and was maintained by air flow at 34.2±0.3°C.

Gd-LTSL composed of DPPGOG, DPPC and DSPC with a phase transition temperature of 42.7°C (measured with differential scanning calorimetry) were loaded with Gd-DTPA-BMA (OMNISCAN™, GE-Healthcare, USA) (7,8). Gadodiamide was chosen because this type of contrast agent is approved for use in humans. 100 µl saline solution containing Gd-LTSL (Gd-concentration 32 µmol/kg) were injected into the tumor immediately before performing MRI.

A new experimental setup was implemented allowing simultaneous hyperthermia treatment and imaging on a clinical 1.5 T whole body scanner (MAGNETOM Vision, Siemens Medical Solutions, Germany) using an 8 cm loop-coil. An anatomical survey was performed with high resolution T1 and T2-weighted spin-echo sequences at 37°C. Contrast agent release at 42°C was monitored by T1-weighted spin-echo (TR=300ms; TE=12ms; 0.6x0.3x3mm³, acquisition time= 1:58 min) supplying high image quality considering the small animal. A temperature of 42°C was chosen because of the relevance for hyperthermia treatment and complete contrast agent release which is achieved approximately after 15 min. This allows the use of relative long acquisition times.

Results: In all animals locally T1w-spin echo signal intensity changes were detectable in the tumors (fig.1). The signal change was heterogeneous according to the location of injection. Contrast agent release was investigated in regions (ROIs) that were subjectively chosen in the tumor part with the highest visible change. Within 3±1 min after onset of the elevated water temperature of 41.5±0.1°C a mean signal change of 52 ± 25% was visible. Thereafter the signal intensity of these ROIs showed a decrease within 33±7min. After this time period and after cooling to the initial temperature of 37°C the signal intensity was not fully reversibly. The reversibility values in two cases had to be excluded for technical reasons (motion at the end and lower temperature of the bath). Signal intensity changes within ROIs in other tumor parts, which show no obvious signal increase, were also detectable. In one tumor ROI the signal intensity did not decrease after the initial increase probably due to low perfusion in this tumor part.

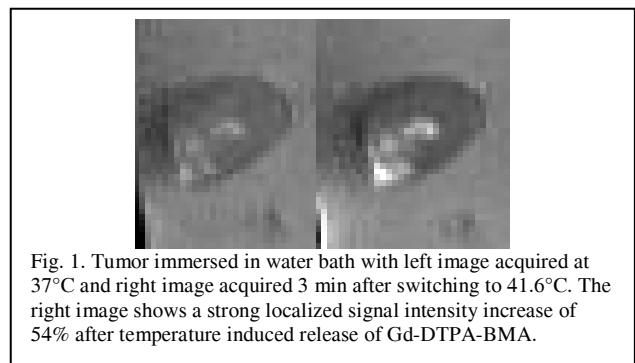


Fig. 1. Tumor immersed in water bath with left image acquired at 37°C and right image acquired 3 min after switching to 41.6°C. The right image shows a strong localized signal intensity increase of 54% after temperature induced release of Gd-DTPA-BMA.

Conclusion: The new Gd-LTSL are locally applicable for MR-monitoring of hyperthermia tumor treatment and are usable in a clinical MRI system. The temperature induced release of contrast agent causes a fast and strong increase of T1-weighted signal intensity in presence of tumor perfusion. Due to tumor perfusion the signal decreases after the initial increase. Contrast agent is not completely washed out during the imaging time. These results demonstrate the feasibility of monitoring hyperthermia tumor treatment in a clinical MRI-system using Gd-LTSL. Further experiments are planned to investigate the use of the Gd-LTSL after intravenous injection.

References:

- (1) Issels, R. *Onkologie*, 22, 374, 1999.
- (2) Falk, M. et al *Int. J. Hyperthermia*, 17(1), 1, 2001.
- (3) Fossheim, SL. et al *Acad. Radiol.*, 7(12), 1107, 2000.
- (4) Viglianti BL, et al. *Magn. Reson. Med.* 51, 1153, 2004
- (5) Lindner, LH. et al *Int. J. Hyp.*, 21(6), 575, 2005.
- (6) Lindner LH, et al. *Clin. Cancer. Res.* 10, 2168, 2004.
- (7) Reinl, HM. *ISMRM* 11, 1209, 2003.
- (8) Wang, T. et al. *ISMRM* 14, 1828, 2006