

Myocardial Contour Propagation in Cine Cardiac MRI

W. Feng¹, H. Gupta², S. Lloyd², L. J. Dell'Italia², and T. S. Denney Jr.¹

¹Electrical and Computer Engineering, Auburn University, Auburn, AL, United States, ²Cardiovascular Disease, University of Alabama at Birmingham, Birmingham, AL, United States

INTRODUCTION

Cine cardiac MRI sequences are commonly contoured at end-diastole (ED) and end-systole (ES) to compute volumes, mass, and ejection fraction [1]. If the remaining frames of the sequence could be easily contoured, then computation of other parameters of LV function (e.g. diastolic filling rates) would be simplified. All frames in a sequence are typically not contoured because manual or semi-automatic methods are tedious and fully-automatic methods are often unreliable. The main difficulties are the exclusion of papillary muscles from the endocardial contour and contouring the epicardium. In this paper, we propose a method to propagate manually-drawn endocardial and epicardial contours to all remaining frames in a cine sequence. The basic idea is that the manually-drawn contours specify how the papillary muscles should be excluded and the location of the epicardium. Non-rigid, mean-square image registration is then used to propagate this information to other frames.

THEORY

Given two adjacent time frames in a cine sequence, our method registers one image to the other by minimizing the mean square error between one image and a deformed version of the other. To avoid local minima and reduce computation, multi-resolution iterative registration is employed [2]. Cubic B-spline interpolation is used in each iteration to reduce interpolation artifacts. Cubic B-splines are also used to model the inter-frame deformation. The number of control points in the deformation field model is adjusted in each resolution layer to maintain an intrinsic regularization.

Let ROI_r and I_t be the automatically-determined region of interest (ROI) in a reference image and target image respectively. Let μ be a vector of deformation field control parameters. Let $\mathbf{m}(\mathbf{x};\mu)$ be the geometric deformation associated with μ at \mathbf{x} . The mean square cost function describing the difference between the reference image and the deformed target image is defined as:

$$S(ROI_r, I_t; \mu) = \|I_t(\mathbf{m}(\mu)) - ROI_r\|_2^2$$

S is minimized using steepest descent algorithm, where the derivative of S with respect to one of the deformation field parameters, μ_i , is given by

$$\frac{dS}{d\mu_i} = 2(I_t(\mathbf{m}(\mu)) - ROI_r) \frac{dI_t(ROI_r; \mathbf{h})}{d\mathbf{h}} \bigg|_{\mathbf{h}=\mathbf{m}(\mu)} \frac{d\mathbf{m}(\mu)}{d\mu_i}$$

METHODS

18 normal human volunteers were imaged with an SSFP sequence with the following parameters: TR 3.8, TE 1.6 ms, slice thickness 8mm, no inter-slice spacing, flip angle 45 deg, k-space segmentation 10 views per segment, matrix 256x128, field of view 42 cm, 1 signal average, bandwidth 125kHz. In each study, a mid-ventricular, short-axis slice was selected. Contours were drawn at ED, which was taken to be the first time frame, and ES by an expert user. These contours were then automatically propagated to the remaining time frames in the sequence by the method described above. The ES contour was propagated to 3 previous and 6 next time frames. Contours in the remaining frames were propagated from ED. The automatically propagated contours were compared to contours drawn by an expert user. Agreement between contours was measured by the mean and maximum unsigned distance between a point on the propagated contour and the closest point on the expert contour. False positive and false negative percentages were also computed. For endocardial contours, the false positive and negative percentages were defined as the number of pixels falsely enclosed or excluded by the contour as a percentage of the total number of pixels enclosed in the expert contour. For epicardial contours, the percentages were defined relative to the total number of pixels in the expert-defined myocardium.

RESULTS AND DISCUSSION

Fig 1 shows the mean and maximum unsigned distance errors in the 18 normal human studies and the false positive and false negative percentages. The mean positioning errors for endocardium and epicardium contours are less than 2mm and 1.2mm with standard deviations of less than 1mm. The maximum positioning errors are less than 4mm and 3mm respectively with standard deviations less than 2mm, which are slightly smaller than errors reported by the active-contour-based algorithm in [3]. Note that the errors do not go exactly to zero because end-systole is not always in the same frame in each study. Higher false positive percentages indicate a larger region enclosed by the propagated contours. Conversely, higher false negative percentages indicate a smaller region enclosed by the propagated contours. These percentages are a measure of the changes in blood volume and myocardial mass due to differences in contouring. Both false positives and false negatives are around 10% for both endo and epi.

Fig. 2 shows an example image in mid-diastole overlaid with both the expert and propagated contours. Note that the propagated contour shows good agreement with the expert contour on the epicardium and excludes the papillary muscles on the endocardium.

CONCLUSION

Short-axis myocardial contours drawn by an expert user at ED and ES can be accurately propagated to other timeframes in a cine sequence.

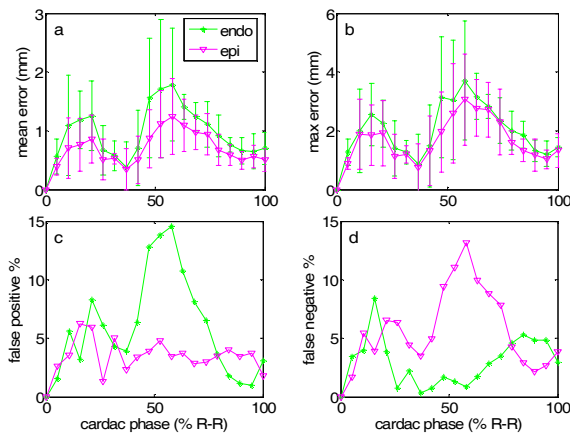


Fig. 1 (a) mean and (b) maximum position error; (c) false positives and (d) false negatives.

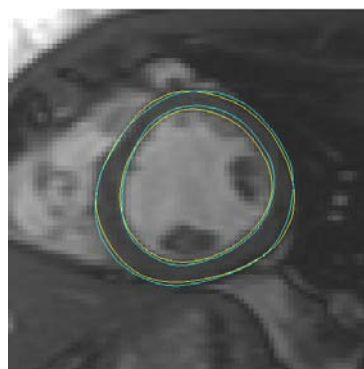


Fig.2 expert (yellow) and propagated (cyan) contours for a mid-diastole cardiac MRI image

REFERENCES

- [1]. A.F. Frangi, W.J. Niessen, M.A. Viergever, "Three-dimensional modeling for functional analysis of cardiac images: A review," *IEEE Trans Med Imaging*, vol. 20, no. 1, pp. 2-25, 2000
- [2]. J.P.W. Pluim, J.B. Antoine Maintz, M.A. Viergever, "Mutual-information-based registration of medical images: a survey", *IEEE Trans Med Imaging*, vol. 22, no. 8, pp. 986-1004, 2003
- [3]. G. Hautvast, S. Lobregt, M. Breeuwer, and F. Gerritsen, "Automatic contour propagation in cine cardiac magnetic resonance images", *IEEE Trans Med Imaging*, vol. 25, no. 11, pp.1472-1482, 2006