

# Super-Resolution for Whole Body Diffusion-Weighted MRI

X. Yin<sup>1</sup>, A. Katsaggelos<sup>2</sup>, J. Deng<sup>3</sup>, D. Wang<sup>3</sup>, R. Omary<sup>1,4</sup>, and A. Larson<sup>1,4</sup>

<sup>1</sup>Departments of Radiology and Electrical Engineering and Computer Science, Northwestern University, Chicago, IL, United States, <sup>2</sup>Departments of Electrical Engineering and Computer Science, Northwestern University, Evanston, IL, United States, <sup>3</sup>Department of Radiology and Biomedical Engineering, Northwestern University, Chicago, IL, United States, <sup>4</sup>Robert H. Lurie Comprehensive Cancer Center, Northwestern University, Chicago, IL, United States

**Introduction:** Early detection of metastatic disease is critical for optimal treatment but whole-body MRI screening remains technically challenging. Recent developments in whole-body MRI have included diffusion-weighted imaging (DWI) with projection of axial 2D stacks to generate large field-of-view coronal images with reversed 'PET-like' contrast for rapid screening [1]. Slice thickness is limited for these techniques and therefore the resulting volumetric datasets provide relatively poor spatial resolution along the cranial-to-caudal orientation potentially limiting capabilities for detecting small metastases. The purpose of our study was to investigate the feasibility of using **super-resolution (SR)** techniques to improve through-plane spatial resolution during multi-slice whole-body DW-MRI. We demonstrate that SR improves through-plane spatial resolution in phantoms and animal models of liver cancer.

**Materials and Methods:** All studies were performed using a 1.5T clinical MRI scanner (Siemens Magnetom Sonata). For DWI we used a single-shot spin-echo EPI sequence with the following parameters: TR/TE =3000/80ms, BW=1.5kHz, and 72x128mm<sup>2</sup> FOV. In-plane voxel size was 1x1 mm<sup>2</sup>. For animal studies 'PET-like' contrast was produced by reversing gray scale signal intensity values.

**Phantom Studies** Six multi-slice stacks with relatively low through-plane spatial resolution were acquired in an orientation orthogonal to the resolution markers of a Siemens Multipurpose MRI Phantom. Each stack consisted of 15 slices with 6mm thickness. To permit super-resolution reconstruction, each of the 6 image stacks were acquired with serial 1mm through-plane shifts from the previous image set. For comparison purposes a high through-plane spatial resolution data set was acquired with 2mm slice thickness.

**Animal Studies** Animal experiments were performed in 4 VX2 liver tumor rabbits. Data sets were acquired according to the procedures discussed in the phantom study with 2D imaging stacks positioned in an axial orientation.

**Super-Resolution Reconstruction** The data model to be considered is:  $g = Df$  where  $g$  is the low resolution data set,  $D$  is the point spread function (PSF), and  $f$  is the high resolution data. High resolution data was iteratively reconstructed:  $f_{k+1} = BD^T g + (-BD^T D)f_k$  using iterative image restoration algorithm [3], where  $B$  is the convergence factor. We approximated the PSF of our SS-SE-EPI sequence by manipulating a simulated RF profile to reproduce 2mm phantom slice data. Using the 6 stacks of shifted 6mm slice-thickness datasets we used SR to produce high-resolution multi-slice image volumes with a) 2mm slice thickness to match our comparison data sets and b) 1mm slice thickness which was beyond our current pulse sequence limitations.

**Results:** All phantom data sets are displayed using a coronal view with RO and SS directions along the vertical and horizontal dimensions respectively. Multi-slice DW-MRI image volumes reconstructed with zero-padding (ZP), interleaving (IN), and SR at 2mm (**Group I**) and 1mm (**Group II**) slice thickness are depicted in **Fig. 1**. ZP and IN failed to differentiate the 3mm resolution markers depicted with SR reconstruction. SR also clearly improved resolution marker depiction compared to ZP and IN in Group II. SR in Group II was able to discriminate these markers comparably to that of the gold-standard (GS) TSE image with 1mm slice thickness. Representative axial and coronal contrast-enhanced anatomic images of VX2 rabbit liver tumors (**Fig. 2A-C**) provide a frame of reference for the reversed-contrast projected 'PET-like' DWI for images from the rabbit depicted in **Fig. 2 Groups I and II**. SR tumor depiction was comparable to reference HR images and superior to ZP and IN. Group II SR images demonstrated the potential to increase through-plan resolution beyond sequence limitations. MSE between SR and reference converged at ~400 iterations (**Fig. 3**).

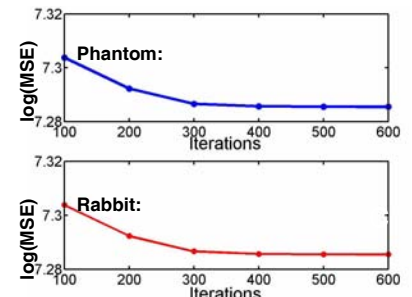

**Conclusion:** SR techniques can improve through-plane spatial resolution for reversed-contrast 'PET-like' DWI. These improvements could potentially increase sensitivity for detecting small metastasis during whole-body screening procedures.

## Fig. 1 Resolution Phantom Studies:

(Each image set was reconstructed from LR multi-stack 6mm slice-thickness datasets)

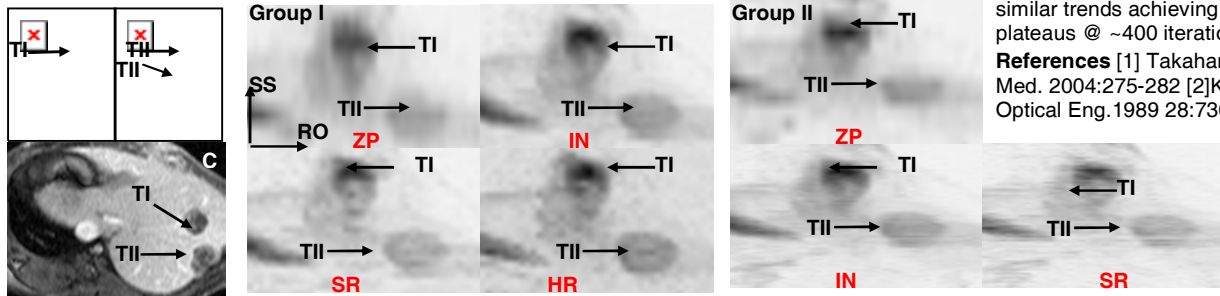
**Group I** 2mm slice-thickness reconstruction

**Group II** 1mm slice-thickness reconstruction zero-padding (ZP), interleaving (IN), super-resolution (SR), high-resolution reference (HR), gold standard (GS) scanned by Turbo Spin Echo sequence at 1mm slice thickness. Group I SR improved resolution marker depiction along SS dimension compared to ZP and IN and was comparable to HR. Group II SR improved resolution in the SS dimension compared to ZP and IN and was comparable to the GS.



**Fig. 3** Mean Square Error (MSE) as a function of SR iteration for phantom (top) and animal (bottom) studies. Each demonstrated similar trends achieving MSE improvement plateaus @ ~400 iterations.

**References** [1] Takahara, Radiation Med. 2004:275-282 [2]Katsaggelos, Optical Eng.1989 28:736-748



**Fig. 2 Animal Studies:** Contrast-enhanced coronal (A and B at anterior and poster positions respectively) and axial (C) images provide a frame of reference for liver tumor positions (arrows, TI and TII). Reversed-contrast, projected 'PET-like' DWI images reconstructed from LR multi-stack 6mm slice-thickness datasets: **Group I** with 2mm slice-thickness reconstruction, **Group II** with 1mm slice-thickness reconstruction with arrows indicating tumor positions. Group I SR clearly demonstrates resolution improvements over ZP and IN comparable to the HR dataset. Group II images demonstrate the potential to use SR reconstruction to achieve through-plane spatial resolution (1mm) beyond that capable with current DWI sequence.