

# DTI in Alzheimer's disease (AD) and mild cognitive impairment (MCI): rapid reproducible analysis of corpus callosum fiber integrity can predict conversion from MCI to AD

B. Stieltjes<sup>1</sup>, P. Thomann<sup>2</sup>, F. L. Giesel<sup>1</sup>, M. Schlüter<sup>3</sup>, H. K. Hahn<sup>3</sup>, J. Schröder<sup>2</sup>, and M. Essig<sup>1</sup>

<sup>1</sup>Radiology, DKFZ, Heidelberg, Baden-Württemberg, Germany, <sup>2</sup>Psychiatry, University of Heidelberg, Heidelberg, Baden-Württemberg, Germany, <sup>3</sup>MeVis, Bremen, Bremen, Germany

## Introduction

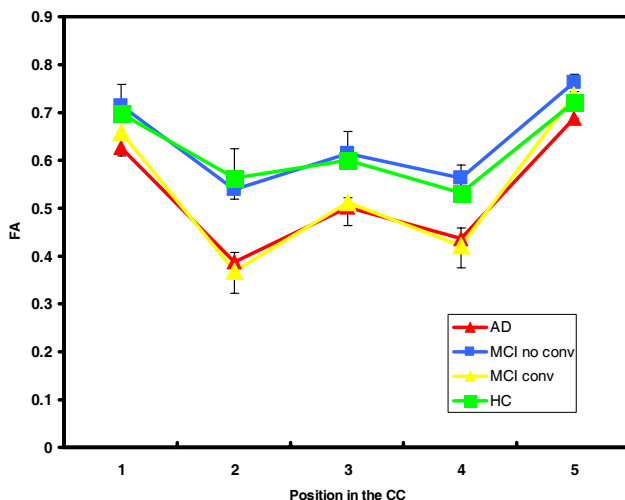
Alzheimer's disease (AD) is the most frequent among the diversity of dementing disorders (80%). It is generally accepted that mild cognitive impairment (MCI) represents its preclinical stage, defined by slight but consistently verifiable deficits that do not allow diagnosis of dementia. In larger clinical studies, subjects with mild cognitive impairment are found to be at a high risk of developing AD, with conversion rates of ~50% over a 3-year time period (1). The early recognition of the subgroup of patients with MCI that will develop AD is pivotal to early interventional treatment. Imaging studies using ventricle volumetry and spectroscopy could well discern between AD and normal volunteers but have so far failed to discern MCI from healthy controls (2). Several reports indicate that DTI and quantification of the fiber integrity may be a tool for early detection of MCI (3) but reproducibility of the quantification methods is limited and data analysis generally time consuming. We have recently presented a fast method for automated ROI-analysis based on probabilistic voxel classification for quantification of corpus callosum (CC) fiber integrity (4). Here, we present data of a longitudinal study on 33 patients with memory complaints (15 AD, 18 MCI) and 15 healthy aged matched controls.

## Methods

All subjects were clinically examined using the mini mental state exam (MMSE). After inclusion, all patients and healthy controls underwent an MRI exam including conventional imaging to exclude other causes of dementia and DTI. All included patients were clinically re-examined yearly and the MMSE-score was used to evaluate conversion to AD in the MCI group. The DTI-exam was performed on a 1.5T scanner and a quadrature head coil (Magnetom Symphony, Siemens Medical Solutions, Erlangen, Germany). Gradient strength 40 mT/m, SSEPI, parameters: TR/TE 4700/78, FOV 240 mm, matrix of 96x96, 50 axial slices, thickness 2.5 mm, 6 gradient directions and two b-values (0 and 1000 s/mm<sup>2</sup>) and 10 averages. Using the aforementioned method for fiber quantification, we measured the FA at five different positions of the CC (genu, 1<sup>st</sup>, 2<sup>nd</sup> and 3<sup>rd</sup> part of the body and the splenium). All measurements were performed by two independent readers blinded to the patient group as well as to results of the other reader. Intra- and interreader variability was evaluated by Intra Class Correlations (ICC) between these measurements using Stata 9.0 (Stata Statistical Software: Release 9. College Station, TX: StataCorp LP.). FA Values of the MCI and AD group were compared to age-matched controls with analysis of variance. An alpha value of <0.05 was chosen as significance level. Also, we compared the FA within the MCI group between conversions and non conversions.

## Results

All patients in the MCI group had comparable initial MMSE scores (26-28) In this group, 10 patients showed conversion ( $\Delta$  MMSE= -3,2 SD=1,1) and 8 patients did not show conversion ( $\Delta$  MMSE=0 SD=0.7). For all subjects, all five measurement points were compared within and between readers. Comparison of the first and second measurement of reader 1 and 2 yielded an ICC-value of 0.997 and 0.994 respectively indicating good intra-reader agreement. Comparison of all four measurements (two measurements of reader 1 and two measurements of reader 2) yielded four ICC-values ranging between 0.997 and 0.998, indicating good inter-reader agreement as reported before (3). Fig.1 shows the measured FA in the AD group, the control group and the two MCI groups. The most pronounced difference in FA was found in the first third of the body of the CC (position 2). The FA at this position was significantly lower in AD vs healthy controls ( $F(1,28)=73.46, p=0.00258$ ) and MCI vs healthy controls ( $F(1,31)=18.59, p=0.0001$ ). When splitting the MCI group in conversion vs no conversion, the converted group showed no significant difference in FA when compared with AD ( $F(1,23)=0.71, p=0.41$ ) whereas the non converted group showed significantly higher FA values when compared to AD and no significant differences from healthy controls ( $F(1,21)=49.31, p=0.00623$ ). Moreover, the FA in the conversion group was significantly lower than in the non conversion group ( $F(1,16)=95.38, p=0.000381$ ).



## Discussion

The presented method for CC fiber integrity measurement proves to be robust and reproducible in this patient group. The method is quick (evaluation time less than 3 minutes) and can easily be incorporated in clinical routine. Using this method, we were able to discern between healthy controls, MCI patients and AD patients. Moreover we found a significant drop in FA in the first 3<sup>rd</sup> of the body of the CC in patients with MCI before conversion to AD. This indicates that DTI of the CC can be used as a fast and reliable method for the evaluation of patients with early forms of AD. The changes we found in the body of the CC correspond with a recently published volumetry study (5). In comparison to the studies however, the proposed method is significantly faster. We will further explore this approach to further validate the found results.

**Fig. 1: mean FA and SD in the 5 positions of the CC:** Green and blue lines show controls and MCI non converters, red and yellow show AD and MCI converters. Note the largest difference at position 2.

## References

1. Mild cognitive impairment: clinical characterization and outcome Petersen RC et al. Arch Neurol 1999; 56: 303-308.
2. Predictors of conversion to dementia of probable Alzheimer type in patients with mild cognitive impairment. Modrego PJ. Curr Alzheimer Res. 2006 Apr;3(2):161-70.
3. Diffusion tensor imaging in early Alzheimer's disease. Naggara O, et al. Psychiatry Res. 2006 Apr 30;146(3):243-9.
4. Diffusion tensor imaging in primary brain tumors: reproducible quantitative analysis of corpus callosum infiltration and contralateral involvement using a probabilistic mixture model. Stieltjes B, et al. Neuroimage. 2006 Jun;31(2):531-42.
5. Structural changes of the corpus callosum in mild cognitive impairment and Alzheimer's disease. Thomann PA et al. Dement Geriatr CognDisord. 2006;21(4):215-20.