

Phantom Experiments with a Novel MR-Guided Transrectal Prostate Interventional System

A. Krieger¹, C. Csoma², P. Guion³, I. Iordachita², G. J. Metzger⁴, D. Qian⁵, A. Singh³, L. L. Whitcomb¹, and G. Fichtinger^{2,5}

¹Department of Mechanical Engineering, Johns Hopkins University, Baltimore, Maryland, United States, ²CISST Engineering Research Center, Johns Hopkins University, Baltimore, Maryland, United States, ³Radiation Oncology Branch, NCI - NIH-DHHS, Bethesda, Maryland, United States, ⁴Center for Magnetic Resonance Research, University of Minnesota, Minneapolis, Minnesota, United States, ⁵Department of Radiology, Johns Hopkins University, Baltimore, Maryland, United States

Introduction:

MRI guided needle placement in the prostate can provide improved accuracy and soft-tissue targeting in comparison to the present-day standard of ultrasonic guided interventions [1]. Transrectal MRI guided prostate interventions, such as biopsies and gold marker placements inside a high-field MR scanner have been reported in initial clinical trials, utilizing active [2] and passive fiducial tracking [3]. This paper reports initial phantom trials of a new system for MRI guided transrectal prostate interventions. This system employs novel probe mechanics and a novel hybrid tracking method, with the goals of (a) shortened procedure time and (b) significantly simplified deployment of the system on different scanners, without any compromise on previously achieved needle placement accuracy [2,4].

Materials/Methods:

Figure 1 shows a photo of the interventional device placed in a standard prostate phantom (CIRS Inc, Norfolk, VA). The interventional device incorporates a hybrid tracking method, which is comprised of a combination of passive fiducial marker tracking and joint encoders. At the beginning of the procedure, the initial position of the interventional device in scanner coordinates is obtained from MR images by segmenting fiducial markers placed on the device. In our new design, from the initial position of the interventional device, motion along all its degrees of freedom is inferred by mechanical scales and MR compatible fiber optic joint encoders, providing inexpensive redundant encoding for increased safety. The interventional device employs two gadolinium fiducial marker tubes (Beeley Corp., Bristol, CT) incorporated into the main axis of the device and two marker tubes placed in line with the needle channel. A thin slab of 1 x 1 x 1 mm isotropic, sagittal, proton density (PD) weighted TSE images in the plane of the markers is obtained. Automatic segmentation of the markers is achieved using a custom targeting software. The software reformats the sagittal images as axial images along the main axis of the interventional device and along the needle axis. In these reformatted axial images the tubular markers appear as circles, allowing for precise automatic segmentation of the fiducial marks. The position of the two axes can then be calculated, thus defining the position of the interventional device.

The three degrees of freedom available to reach a target from this initial position include rotation of the probe, pitch (angle) of the needle, and insertion of the needle. Rotation and needle angle are encoded separately by mechanical scales placed on the interventional device. As a more precise alternative to the mechanical scales, MRI compatible quadrature fiber-optic encoders with an angular resolution of 0.25 degrees built using photoelectric sensors with plastic fibers (Banner Engineering Corp., Minneapolis, Minnesota) are currently being incorporated and tested. Insertion of the needle is accomplished manually by using the scale on the needle to determine depth. The targeting software provides the necessary rotation, needle angle, and needle depth for a given target.

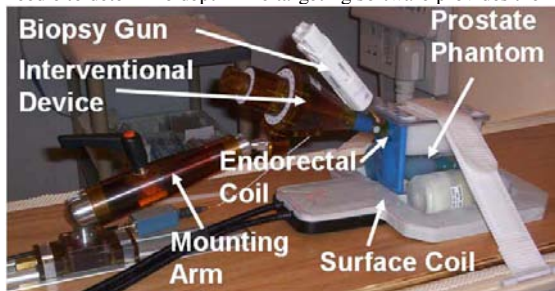
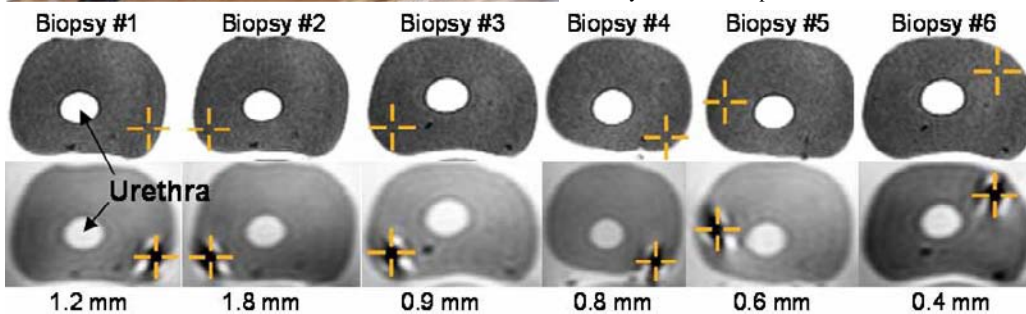


Figure 1 (left): Photo of the new MRI-guided transrectal imaging and biopsy device with the endorectal imaging coil placed in a prostate phantom. The device is locked in place by a mounting arm. The prostate phantom is placed on a surface coil, which enhances signal, especially for the posterior part of the prostate.

Figure 2 (below): Targeting images, needle visualization images, and in plane errors for six biopsies of a prostate phantom. **Top image row:** A target (orange cross hair) within the prostate of the phantom is selected on an axial TSE T2-weighted image. **Bottom image row:** The needle tip void is visualized in an axial TSE proton density image. It can be seen that the desired target matches the actual position of the needle. **Bottom number:** The number indicates the in-plane targeting error for the needle placement. In-plane error is the distance between target and needle center in the plane axially to the needle path.



References:

- [1] Yu KK. Radiol Clin North Am 2000;38:59.
- [2] Krieger A. Trans on Biomed Eng, 52(2):306-313, 2005.
- [3] Beyersdorff D. Radiology, 234(2):576-581, 2005.
- [4] Susil RC, J Urol, 175(1):113-20, 2006.

Results:

The system for MRI guided transrectal prostate interventions was tested in a phantom experiment on a 3T Philips Intera MRI scanner (Philips Medical Systems, Best, NL). The interventional device was placed in a prostate phantom. The interventional device was imaged in the phantom using an isotropic 1mm x 1mm x 1mm proton density weighted TSE sagittal image sequence with a scan time of 2 minutes and 30 seconds. The four passive gadolinium marker tubes, placed along the axis of rotation and on the needle axis were automatically segmented by the targeting software, registering the location of the interventional device in scanner coordinates. Six targets were selected within all areas of the prostate on T2 weighted axial TSE images (Figure 2). For each target, the interventional device was moved according to targeting parameters provided by the software, followed by biopsy needle (Invivo Germany GmbH, Schwerin, Germany) insertion. The final location of the needle was confirmed by acquiring axial TSE proton density images which show the void created by the needle tip close to the target point.

The in-plane error for each of the six biopsies was subsequently calculated to assess the accuracy of the system. The average in-plane error was 0.9 mm with a maximum error of 1.8 mm. The out of plane error is not critical in biopsy procedures due to the length of the biopsy core and was not calculated. The procedure time for the six biopsies was 45 minutes.

Discussion and Conclusions:

The phantom experiment demonstrated the feasibility of performing prostate interventions with the proposed system. The phantom experiment showed good coverage of the prostate gland and demonstrated accurate and fast needle targeting of the prostate. The errors and procedure time compare favorably to average reported accuracy results of 1.8 mm and average procure times of 76 minutes, using active tracking method in initial clinical trials [4]. The hybrid tracking method allows this system to be used on any MRI scanner without extensive systems integration and calibration. Fiber-optic encoders with an angular resolution of 0.25 degrees will be added to the current mechanical scales for joint encoding, thereby further increasing the accuracy and safety of the system. IRB approvals are pending at multiple clinical sites. Initial clinical results will be reported at the conference.

Acknowledgements:

The authors gratefully acknowledge our support under grant NIH RO1 EB02963 and the help of Dr. P. Choyke, Dr. I. Ocak, and J. Sedlacko with this experiment.