

# THE INFLUENCE OF TEMPORAL RESOLUTION AND PHASE-ENCODING ORDER ON SHAPE-BASED CLASSIFICATION OF DYNAMIC CONTRAST ENHANCED (DCE) MRI UPTAKE CURVES IN THE BREAST

M. Heisen<sup>1</sup>, T. Twellmann<sup>1</sup>, H. Buurman<sup>2</sup>, A. Vilanova<sup>1</sup>, F. A. Gerritsen<sup>1,2</sup>, and B. M. ter Haar Romeny<sup>1</sup>

<sup>1</sup>Biomedical Image Analysis, Technische Universiteit Eindhoven, Eindhoven, Netherlands, <sup>2</sup>Healthcare Informatics - Advanced Development, Philips Medical Systems, Best, Netherlands

## Introduction

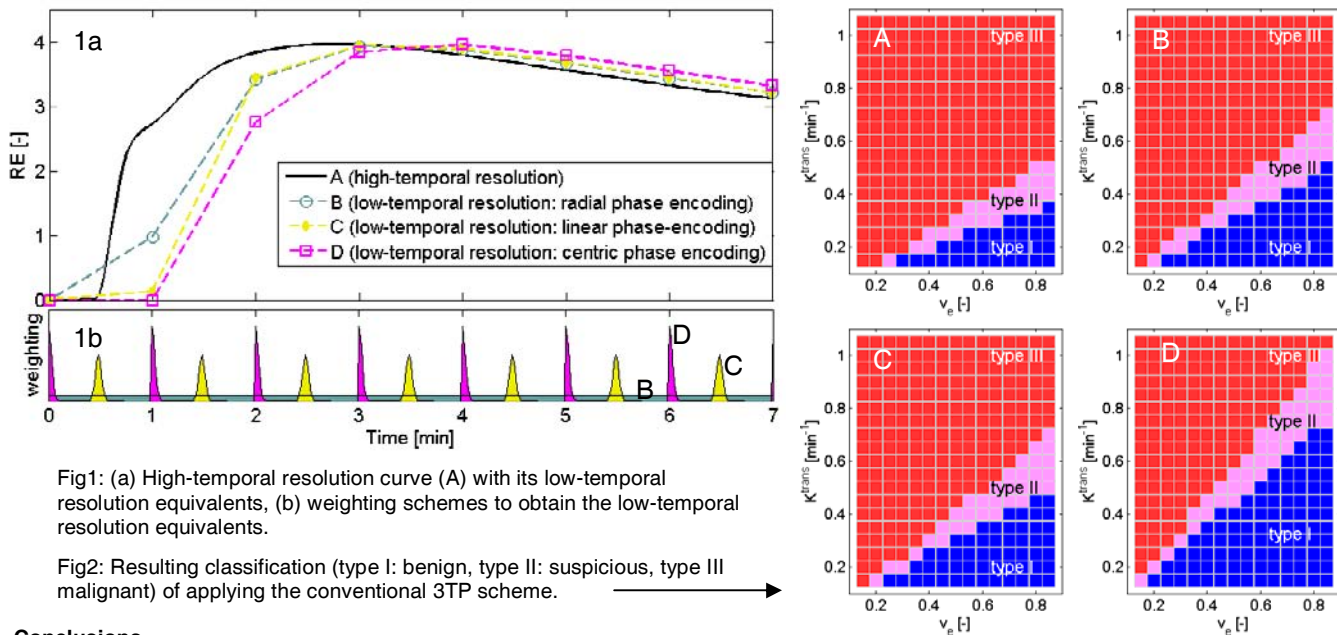
In DCE-MRI of the breast a  $T_1$ -weighted dynamic imaging series is recorded during the uptake of a contrast agent (CA), usually Gd-DTPA. In clinical practice, temporal resolution is relatively low compared to the time-scale of the uptake process. This means that the signal intensity of voxels can change significantly *during* the acquisition of each dynamic. Depending on the applied protocol, each point of an uptake curve can represent, for instance, a certain time-point within the image-acquisition interval (as in linear or centric phase-encoding) or the whole image-acquisition interval (as in radial phase-encoding used in THRIVE). Thus, it is not necessarily a representation of the signal at the time-point that is assigned to the image (usually end of acquisition). This is due to the fact that the center of k-space, and therefore the timing of the acquisition of the central k-lines, is dominant in determining the overall signal intensity and contrast. Once we can use a higher temporal resolution, this undesired influence will diminish so that the obtained curve will more closely resemble the true uptake curve. However, this also means that the conventional curve classification schemes, such as Kuhl's shape model [1] or the Three-Time-Point scheme (3TP) [2], will no longer be appropriate, since they have been developed and statistically validated for classification of low-temporal resolution curves. It appears that, until now, the variations caused by phase-encoding order and/or temporal resolution have been neglected. In this paper, we investigate the effects of these variations on shape-based curve classification.

## Material and methods

In order to show the extent of these effects, high-temporal resolution uptake curves are simulated with a pharmacokinetic model (basic Kety [3]) for a reasonable range of  $K^{\text{trans}}$  ( $0.1\text{-}1.3 \text{ min}^{-1}$ ) and  $v_e$  ( $0.1\text{-}0.8$ ) [4]. We have chosen to simulate a delay of 25 s between the start of acquisition (at end of injection) and arrival of the CA in the breast ( $\pm 15$  s delay between end of injection and beginning of arterial enhancement [5],  $\pm 10$  s delay between arterial enhancement and response [6]). In figure 1a an example of a high-temporal resolution uptake curve (A) is given in relative enhancement ( $\text{RE} = (S(t)-S_0)/S_0$ ), together with its low-temporal resolution equivalents (temporal resolution: 60 s). Curve B represents the THRIVE protocol with radial phase-encoding, which is approximated by averaging the RE-values of curve A over the image-acquisition interval. Curve C represents an FFE protocol with a linear phase-encoding order, which is approximated by weighting the RE values of each sampling interval of curve A with a Gaussian function that is centered at the middle of each interval. Curve D represents an FFE protocol as well, but this time with a centric phase-encoding order, which means that the weighting is performed with half a Gaussian at the start of each interval. The weighting schemes are illustrated in figure 1b. The obtained uptake curves are classified with a shape model by means of defining the shape of the contrast-uptake curve as steady, plateau/cutoff or washout. The common 3TP scheme is used: if the RE increases from the second (2 min) to the third time-point (6 min), it is classified as type I (steady); if it stays constant ( $\pm 10\%$ ), it is classified as type II (plateau/cutoff); and if it decreases it is classified as type III (washout) [2].

## Results

In figure 2 the resulting classification is visualized in  $K^{\text{trans}}$ - $v_e$  parameter space, in which each point represents a simulated response of a certain type of tissue. The names of the subfigures correspond to the legend in figure 1. Firstly, by comparing subfigures B, C, and D, it becomes clear that the same tissue (same combination  $K^{\text{trans}}$ - $v_e$ ) can be classified differently due to a difference in phase-encoding order. The difference between radial (B) and linear (C) phase-encoding is small, whereas they both show a large difference with centric (D) phase-encoding. Secondly, by comparing subfigure A on one hand and B, C, and D on the other hand, it shows that the application of the conventional 3TP scheme on high-temporal resolution curves results in false positives; i.e. the fraction classified as type III (indicative for malignancy) is larger in A than in any of the low-temporal resolution cases.



## Conclusions

We have shown two things by means of simulations: (1) the phase-encoding order influences the result of 3TP-curve classification for acquisitions with routine low-temporal resolution and (2) by applying the 3TP scheme on high-temporal resolution curves, there are cases that will be misclassified. Radiologists should be aware of these effects when analyzing the data visually or with the aid of software tools.

(1) C. K. Kuhl et al., *Radiology*, 1999.

(3) P. S. Tofts et al., *Magn. Reson. Med.*, 1995.

(5) T. Fritz-Hansen et al., *Magn. Reson. Med.*, 1996.

(2) F. Kelcz et al., *AJR*, 2002.

(4) E. Henderson et al., *Magn. Reson. Imaging*, 1998.

(6) C. Boetes et al., *Radiology*, 1994.