

# Iron Deposition in the Putamen

B. Krishnamurthy<sup>1</sup>, E. M. Haacke<sup>1,2</sup>, M. Ayaz<sup>2</sup>, S. Harder<sup>3</sup>, D. Kido<sup>4</sup>, W. Kirsch<sup>5</sup>

<sup>1</sup>Biomedical Engineering, Wayne State University, Detroit, Michigan, United States, <sup>2</sup>The MRI Institute for Biomedical Research, Detroit, Michigan, United States,

<sup>3</sup>Medical Imaging, University of Saskatchewan, Saskatoon, Saskatchewan, Canada, <sup>4</sup>Radiology, Loma Linda University, Loma Linda, California, United States,

<sup>5</sup>Neurological Surgery, Loma Linda University, Loma Linda, California, United States

**Introduction:** Iron deposition in the basal ganglia is part of the normal aging process. It is also known that elevated iron content in the basal ganglia is often an indicator of disease. Goal in this paper is to understand the normal variations in iron with an elderly population so that we can differentiate normal from abnormal iron content. Current approaches for extracting iron content use either  $R_2$ ,  $R_2'$  or  $R_2^*$ . In this work, we use the high pass filtered phase images from an SWI (susceptibility weighted imaging) scan. These have been shown to correlate well with iron content in brain tissues.

**Materials and methods:** SWI images were collected at 1.5T using a fully flow compensated, 3D, gradient echo sequence. The normal acquisition parameters were used: in-plane resolution 0.5mm x 1.0mm; TH = 2mm, FOV = 256mm x 256mm; Nx = 512; Ny = 256; Nz = 48; TE = 40ms; TR = 57ms; FA = 20 degrees. The phase images were high pass filtered. A series of 75 subjects were evaluated for an Alzheimer's study (informed consent was obtained in all cases). A series of images covering the putamen were first evaluated. From this group, one representative landmark slice that contained the highest iron content was chosen. This slice was easily found from subject to subject. Out of 75 subjects, 43 were evaluated by one observer, trained by senior observers dividing the putamen into 4 different parts. Subjects ranged in age from 55 to 89 years old. The putamen was broken into 4 parts as shown in the figure 1 below (2) (1). The advancing iron content has been shown by others to follow a path through the putamen relating to the increase in iron content from the lower outer, to lower inner, upper inner and finally the upper inner region. Great care was taken in drawing the regions-of-interest in all the cases. The upper inner region rarely had iron changes and the histogram of phase values was used to choose the threshold below which one would then say that there was significant excess iron present in the tissue. This threshold was chosen using the mean minus two standard deviations which was found to be 1925 units of phase (on this scanner, Siemens Vision, a phase of 0 corresponds to 2048 and a phase of  $\pi$  to 4096). The mean values for all four parts were compared with this threshold, if the values fell below this threshold it was concluded that the region had a higher than normal iron content. The staging criteria were defined as follows:

Stage 0 → No apparent iron build up in the putamen

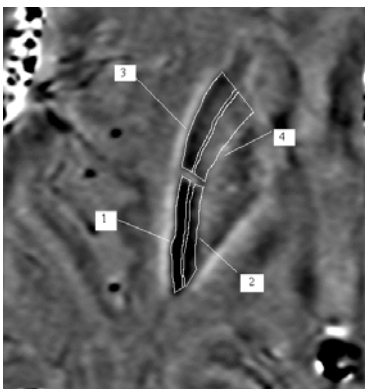
Stage 1 → Lower outer deposited with iron (the phase falls below the pre-determined threshold of 1925)

Stage 2 → Lower inner and lower outer deposited with iron (the phase falls below the pre-determined threshold of 1925)

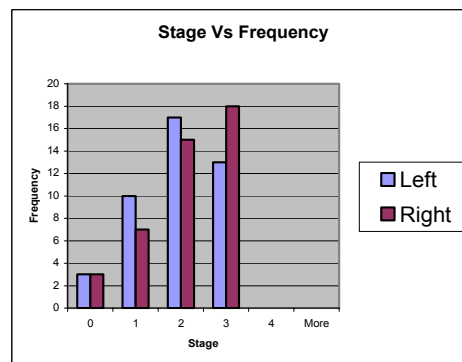
Stage 3 → All regions except the upper inner deposited with iron (the phase falls below the pre-determined threshold of 1925)

Stage 4 → Putamen totally deposited with iron (the phase falls below the pre-determined threshold of 1925)

Stage	Part	Inter-subject mean of the Means	Standard deviation of the Inter-Subject Means
1	Lower Outer	1839	73
2	Lower Inner	1892	71
3	Upper Outer	1972	50
4	Upper Inner	2009	25



**Figure 1**



**Figure 2**

**Table 1**

**Results:** Figure one shows an example stage 3 pattern with iron in regions 1, 2 and 3. Iron deposition starts from the lower outer part of the brain as function of age over the time. This basic pattern was observed in all subjects. The mean intensities for all the four regions were grouped into histograms. Thirty patients were found to be distributed in stages 2 and 3 which accounts for 75 % of the sample. At this age, their seemed to be little dependence on age and stage; when the same histogram was redone for the 6<sup>th</sup>, 7<sup>th</sup> and 8<sup>th</sup> decades of life, the shape of the histogram remained invariant. Iron deposition was relatively symmetric in most of our subjects. Table 1 shows the inter-subject average of mean phase values and standard deviation of the means. Iron is not uniformly deposited and we see that the standard deviation increases as the iron content increases showing the heterogeneity of the iron deposits.

**Discussion and Conclusion:** The normal deposition of iron in older subjects appears to start in the lower putamen and extend to the upper putamen. Iron builds up initially in the lower outer region followed by the lower inner region. Next it appears to build up in the upper outer region. We have not yet seen any build up in the upper inner region. Symmetric but non-uniform deposition of iron was seen in this normal population. Knowledge of the normal pattern of mineralization of the putamen in the elderly population may be useful in analyzing the pattern of mineralization in patients with neurodegenerative diseases.

**References:** 1) Steffans DC, McDons WM, Tupler LA, Boyko OB, Krishnan KR. Magnetic resonance imaging changes in putamen iron content and distribution in normal subjects. Psychiatry Research: Neuroimaging. 1996;68:55-61.2) Brain Mineralization with Age, Sheri L. Harder, MD, FRCPC, Department of Medical Imaging, University of Saskatchewan (5<sup>th</sup> Annual SWI Meeting, Miami, May 2005).

NIH grant titled: Iron Metabolism Alterations in Alzheimer's Disease RO1 AGZ0948.