

The study of ulnar variance with high-resolution MRI: correlation with triangular fibrocartilage complex and cartilage of ulnar side of the wrist

H. Yoshioka¹, T. Tanaka², T. Ueno³, J. A. Carrino¹, C. S. Winalski¹, P. Lang¹, B. N. Weissman¹

¹Radiology, Brigham and Women's Hospital, Boston, MA, United States, ²Orthopedics Biomechanics Lab, Mayo Clinic, Rochester, MN, United States, ³Radiology, Iwate Medical School, Morioka, Iwate, Japan

INTRODUCTION

Ulnar variance affects the force distribution across the wrist and is related with some ulnar pathologies. Ulnar minus variance is associated with Kienböck's disease, whereas ulnar plus variance plays an important role in triangular fibrocartilage complex (TFCC) tear and ulnar impaction syndrome. Ulnar variance is measured based on plain radiograph. However, plain radiograph shows poor soft tissue contrast. MRI is an imaging modality with excellent soft tissue contrast, which allows showing TFCC and carpal cartilage clearly with high-resolution technique (1). Therefore, the purpose of this study was to investigate correlations with ulnar variance and TFCC or cartilage of the wrist on high-resolution MRI with a microscopy coil.

MATERIALS AND METHODS

The relationship between ulnar variance and TFCC or cartilage of the lunate and the ulnar head was examined in 93 subjects (29 asymptomatic normal volunteers and 64 patients with wrist pain) with high-resolution MRI using a 47-mm microscopy surface coil. All MR images were obtained with a 1.5 T (Gyrosan NT Intera, Philips Medical Systems, Best, The Netherlands). Each subject was placed in the prone position with the arm extended over the head, simulating a swimming position (forearm pronation) and each surface coil was positioned over the ulnar side of the wrist. Coronal gradient recalled echo (GRE) T2*-weighted images (T2*WI) (TR/TE/ flip angle = 270-608/13-18/40, a 1- to 1.5-mm slice thickness, a 50-mm field of view, an imaging matrix of 140-224 x 512 using zero fill interpolation, and 3-4 excitations) were used for analysis.

As a qualitative analysis, ulnar variance on MRI, TFCC angle, thickness in the mid-portion of TFCC disc proper, and thickness of cartilage of the lunate and the ulnar head were measured. The ulnar variance on MRI was indicated by difference between line at the level of lunate fossa cartilage surface and line at the level of the ulnar head cartilage surface (Figure 1a). TFCC angle was defined as angle between long axis of TFCC and the above lines (Figure 1b). The correlation coefficient among measured values was calculated.

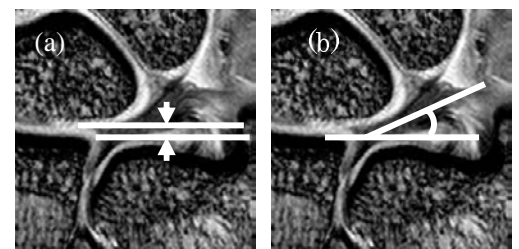


Fig.1 (a) Ulnar variance and (b) TFCC angle measured on MRI

RESULTS

High-resolution MR images with microscopy coil demonstrated TFCC and cartilage of the wrist clearly as well as ulnar plus, zero, and minus variance (Figure 2). The TFCC thickness in 10 patients were not evaluated because they had large disc proper tear. The mean ulnar variance on MRI was 0.26 mm, ranging from -4.59 mm to 3.71 mm. The mean TFCC angle and TFCC thickness were 23.9 degrees (ranging from -4.6 to 54.1 degrees) and 1.11 mm (ranging from 0.4 to 3.22 mm), respectively. The positive correlation between ulnar variance and TFCC angle was seen ($r=0.84$) (Figure 3), whereas negative correlation between ulnar variance and TFCC thickness was seen ($r=-0.71$) (Figure 4). The mean cartilage thickness of the lunate and ulnar head was 1.10 mm and 0.80 mm, respectively. The former was significant thicker than the latter ($p<0.0001$). No significant correlation was demonstrated between ulnar variance and lunate cartilage thickness ($r=-0.10$) or ulnar head cartilage thickness ($r=-0.12$).

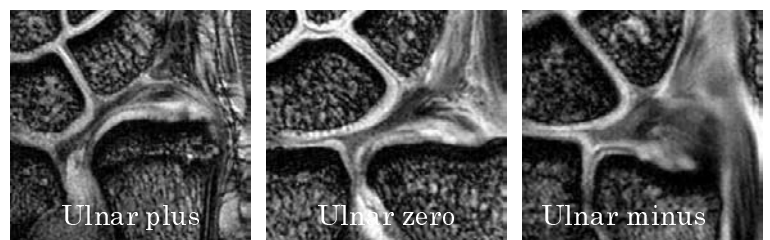


Fig. 2 Ulnar variance

CONCLUSION

Ulnar variance measured on MRI showed a strong correlation with TFCC thickness and TFCC angle, while there was no correlation between ulnar variance and cartilage thickness of lunate and ulnar head. High-resolution MRI with a microscopy coil would be useful to evaluate the pathology of the ulnar side structures of the wrist including TFCC and cartilage associated with ulnar variance.

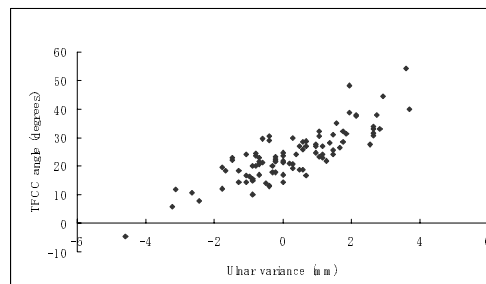


Fig. 3 Ulnar variance vs TFCC angle

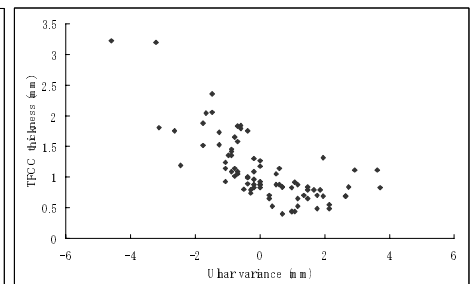


Fig. 4 Ulnar variance vs TFCC thickness

REFERENCES

1. Yoshioka H, Ueno T, Tanaka T, Shindo M, Itai Y. High-resolution MR Imaging of Triangular Fibrocartilage Complex (TFCC): Comparison of Microscopy Coils and a Conventional Small Surface Coil. *Skeletal Radiol* 2003; 23:575-581.