

Does the use of passive occlusion combined with a sialogogue improve MR sialography ?

J. A. Hugill¹, K. G. Hollingsworth², E. Sala², D. J. Lomas²

¹Radiology, Addenbrookes Hospital, Cambridge, Cambridgeshire, United Kingdom, ²Radiology, University of Cambridge, Cambridge, Cambridgeshire, United Kingdom

Introduction Over the last decade MR hydrographic techniques have been described that challenge conventional X-ray based techniques. For example MR cholangio-pancreatography is largely replacing diagnostic ERCP with the advantages of a non-invasive approach that avoids the complications related to endoscopic duct cannulation as well as the ionising radiation. MR based sialography has been described [3] but has been much less widely adopted although the technique can demonstrate calculus related obstruction and established sialectasis [1,2]. The spatial resolution of the technique is more limited for evaluation of the branch ducts and the morphological changes of early sialectasis partly owing the low intrinsic signal to noise ratio (SNR), but also the amount of saliva within the ducts at the time of imaging. Conventional sialography uses cannulation that occludes the duct and a sialogogue, such as citric acid or lemon juice both to aid identification of the duct and to functionally confirm “washout” of the X-ray opaque contrast media after the cannula is withdrawn. Recent work has used a sialogogue for “dynamic MR sialography” [4] and also dedicated surface coils with improved SNR [5] to try and enhance the visibility of the main and branch ducts. This work investigates whether the use of a passive intra-oral occlusal device, similar to those used routinely in dentistry, combined with a sialogogue, to try and increase the volume of fluid within the duct system, can improve the demonstration of the main and branch ducts of the parotid salivary glands when used with a 3D FSE technique and small dedicated surface receive coils.

Method Local Research Ethics Committee approval was obtained along with individual consent from the twelve healthy volunteers (Age 21-56yrs, 8:4 Female:Male) with no history of salivary gland disease recruited for the study.

Study design: The volunteers were examined supine after at least 30 minutes fasting. MR sialography was performed with no additional preparation and then repeated after a minimal delay with an intra-oral occlusion device (made from a gauze swab wrapped in domestic “cling-film” placed between the upper dentition and the orifice of the parotid duct. Pre and post images were acquired on the same side. A sialogogue (2 wedges of fresh lemon) was employed immediately before imaging commenced. In order to try and maintain the head position and comparable locations between the two studies the volunteer remained supine and with the coils attached.

MR protocol: All examinations were performed using a 1.5T whole body MR system (GEHT, Excite). A 4-channel dedicated carotid coil (Flick Engineering Solutions, Holland) was placed on each side of the head adjacent to the parotid glands. A gradient echo localizer was used to identify the position of the parotid duct and gland. Sialograms were acquired using an oblique sagittal 3D FRFSE volume in line with mandibular rami with the following parameters: tailored r.f. pulse, TR/TE/NEX = 6000ms/800ms/4, FOV 20cm, matrix 256x128, 48 sections per volume, RBW 50 kHz, fat suppressed, acq.time 6 minutes).

Analysis: Sialography images for comparison were produced by creating a maximum intensity projection. The last outer plane was identified via skin artefact and eliminated with subjective assessment of the innermost plane to ensure that adequate coverage was obtained through the sections of the 3D acquisition. (fig1). Non-relevant parts of the image were removed, including any additional signal resulting from fluid accumulation around the occlusal device, to ensure effective blinding for the analysis. The images were then read by two experienced radiologists in consensus who were not involved in the data acquisition or image processing. The pre and post lemon images were presented blinded and in random order (left-right, right-left). For both images separately, the radiologists assessed the adequacy of the visualization of: the main duct, secondary ducts and tertiary ducts using a binary scale of 0 = not adequately visualised and 1 = adequately visualised to allow reporting of the study. The radiologists then assessed the images comparatively for visibility of the main duct, secondary ducts, tertiary ducts and image artefact a three point scale where 0 = no difference, 1 = pre better than post and 2 = post better than pre.

Results Both the pre and post occlusion image acquisitions were assessed for adequacy of duct visualisation followed by the presence of significant artefact. These results are represented in fig 2(top). A direct comparison was then made between the pre and post image acquisitions with the results demonstrated in fig 2(bottom). On statistical analysis between the comparison of pre and post ductal occlusion, the main duct was better visualised post occlusion in 100% of cases. Using the one sided sign test the secondary duct was visualised better in the post occlusion image ($p = 0.05$). Adequacy of ductal visualisation using the Wilcoxon signed rank test demonstrated a significant difference post occlusion ($p = 0.05$) for the main duct but the results for secondary and tertiary duct visualisation did not reach significance (secondary $p = 0.06$). The close proximity to a statistical difference with regard to adequacy of secondary ductal visualisation maybe a factor of relatively small numbers as the trend demonstrated did demonstrate improved visualisation. No significant difference was found in artefact between pre and post occlusion images.

Conclusion Our results demonstrate that the use of ductal occlusion in combination with the use of a sialogogue significantly improves the visualisation of the main parotid duct with a trend towards improved visualisation of the peripheral ducts within the parotid gland with no detriment in image quality due to artefact. Further work is necessary to assess the efficacy of the occlusal method and to see if similar results can be obtained in diagnostic patient studies.

References

1. Becker et al. *Radiology* 2000;217:347
2. Kalinowski et al. *AJNR* 2002;23:1485
3. Lomas et al. *Radiology* 1996;200 :129
4. Morimoto et al. *Oral Surg Oral Med Oral Pathol Oral Radiol Endol* 2005;100: 357
5. Takagi et al. *JMRI* 2005; 22:29-37

Acknowledgements Fund and Friends of Addenbrookes, MRIS Unit Radiographers, Addenbrookes Hospital

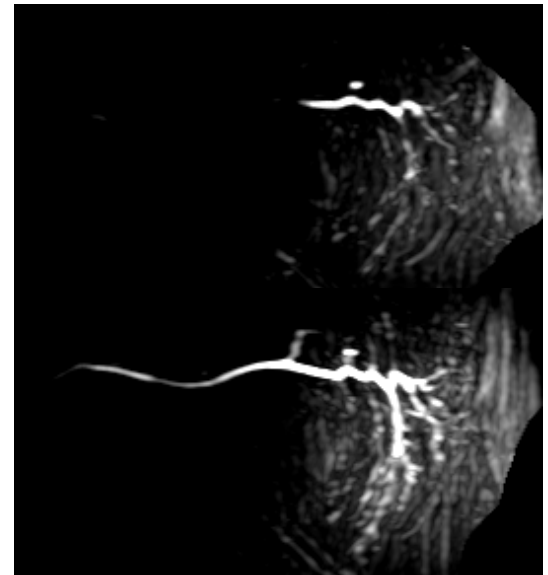


Fig 1: Maximal intensity projection images from 3D acquisitions (top) no preparation (bottom) with occlusion and sialogogue.

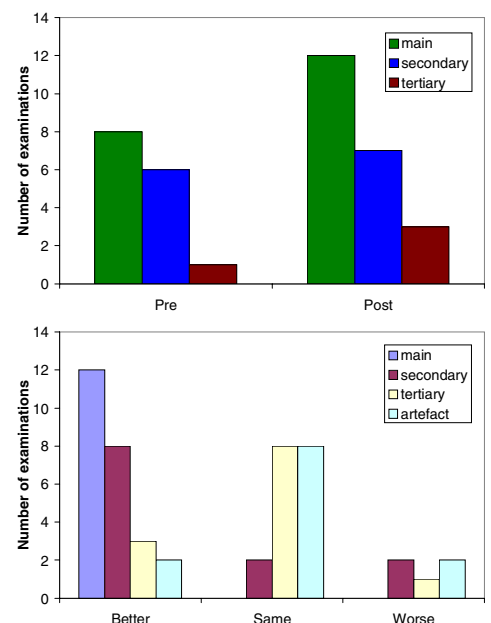


Fig 2: (top) Adequacy of duct visualization. (bottom) Comparison of post with pre-occlusion images (visualization better, same or worse)