

Tract Probability Map in Stereotaxic Spaces and Analysis of Asymmetry

K. Hua¹, J. Zhang¹, S. Wakana¹, H. Jiang¹, P. van Zijl^{1,2}, S. Mori^{1,2}

¹Department of Radiology, Johns Hopkins University, Baltimore, MD, United States, ²Kennedy Krieger Institute, F. M. Kirby Research Center for Functional Brain Imaging, Baltimore, MD, United States

Introduction

DTI-based tract reconstruction (tractography) is an exciting new tool to investigate white matter anatomy non-invasively. However, tractography may contain inaccuracy due to contributions from noise, partial volume effects, and complex axonal structures within a voxel. As a consequence, quantification of morphology is a challenging goal. In this study, we tackled this issue by creating probabilistic maps of 10 major white matter tracts from 28 healthy volunteers, in which random tracking errors should not contribute significantly, and the results were registered in standard coordinates. The probabilistic maps of the normal subjects are available in our websites and can be used as an atlas for white matter anatomy studies. This method can be used to quantitatively compare morphology of tracts of interest between groups. As a first application, we examined right-left symmetry of these tracts in our group.

Method

Twenty-eight healthy adults (mean 26.1 +/- 5.48 years old, male 17, female 11) participated our study. Subjects did not have any history of neurological problems. DTI data were acquired on a Philips 1.5T scanner using single-shot echo-planar imaging with sensitivity encoding (SENSE) factor 2.5. Datasets were processed using home made software DtiStudio. FACT [2] and the multi-ROI approach were used to reconstruct tracts of interest (FA and angle threshold are 0.2 and 41° respectively). Averaged diffusion-weighted images were used for affine AIR [1] registration. The transformation matrix acquired from AIR was applied to the subject's fiber tracts to transform them from subject coordinates to the JHU-DTI template, ICBM-MNI(Avg152), and Talairach spaces. The fibers were then averaged to generate a probability map in each space.

Results and Discussion

Fig. 1 shows results of probabilistic maps of 7 representative white matter tracts reconstructed in this study. The numbers of pixels occupied by the reconstructed fibers are compared in Fig. 2 (right-left follows radiology convention). Both the volume measurements and right-left comparison of probability maps indicated that four association fibers related to the temporal lobes are larger in the left hemisphere. These tracts are, uncinate fasciculus (UNC), temporal projection of the superior longitudinal fasciculus (tSLF), inferior longitudinal fasciculus (ILF) and cingulum (CG). Other fibers including inferior fronto-occipital (IFO), corticospinal tract (CST), anterior thalamic radiation (ATR) were highly symmetric.

The tract probability maps can be considered as white matter segmentation results by using tractography as a region growing tool to group pixels that belong to the same tract system. We expect that his technique is an effective tool to identify specific white matter tracts that account for white matter volume loss. The normal probability maps could also be used to register variously non-DTI data to associate any MR-detected abnormalities (e.g. T2 hyper-intensity) or fMRI data to specific tract families.

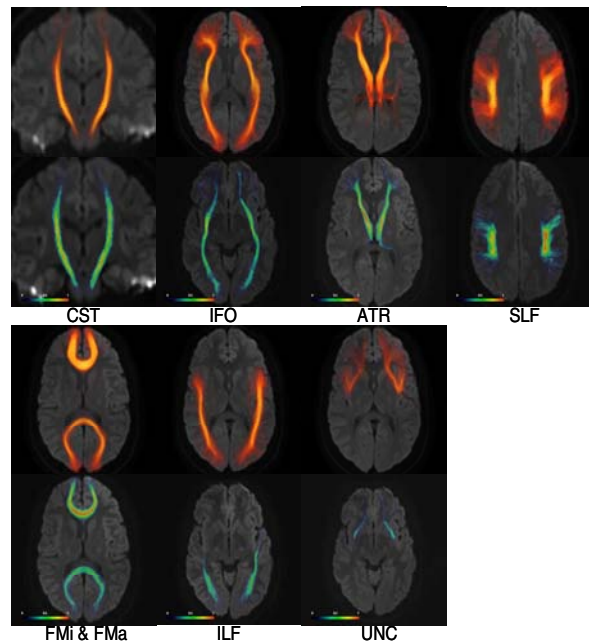


Fig. 1: Volume rendering (upper) and 2-D view (lower) of fiber track probability maps. Abbreviations are in text except for forceps major (Fma) and minor (Fmi).

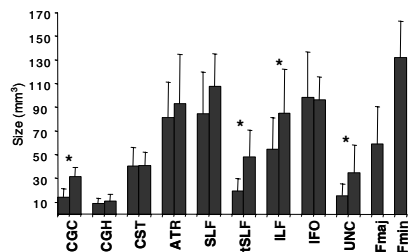


Fig. 2: Track volume comparison. (*: $p < 0.05$)

References

- [1]: R. Woods et al, J Comput Assist Tomogr, **22**: 139-52, 1998
- [2]: S. Mori et al, Annals of Neurology, **45**, 265, 1999