

A Parallel Acquisition Optimized Peripheral Vascular Coil for Combination Time Resolved and High Resolution Peripheral CE-MRA

J. H. Maki^{1,2}, G. J. Wilson³, R. M. Hoozeveen⁴, W. B. Eubank^{1,2}, D. J. Glickerman^{1,2}, J. Whitnah², M. B. Mathis², C. E. Hayes²

¹Radiology, Puget Sound VAHCS, Seattle, WA, United States, ²Radiology, University of Washington, Seattle, WA, United States, ³Philips Medical, Cleveland, OH, United States, ⁴Philips Medical, Best, Netherlands

Introduction

Evaluation of the peripheral arterial vasculature represents one of the most successful applications of contrast enhanced MR angiography (CE-MRA). With the advent of faster imaging systems employing multi-station phased array coils, parallel imaging, faster gradients, view-sharing, and rapid moving table technology, the simplicity and efficiency of single injection techniques has improved to where excellent results are routinely obtained. This work describes a systematic method for combining these advances to custom tailor imaging parameters for each individual patient to optimize a combination of time-resolved and static high-resolution peripheral MRA.

Methods

A prototype six channel per station, 3-station phased array peripheral vascular coil was constructed to optimally incorporate parallel imaging technology (SENSE) at all 3 stations on an Intera (R11) 1.5T scanner (Philips Medical Systems, Best, the Netherlands). [1] A standard examination consists of a Gd timing bolus (1cc) detected in the abdominal aorta (dynamic axial T1-FFE), followed by a second Gd bolus (6cc) with rapid keyhole dynamic 3D imaging of the calf station (coronal T1-FFE, matrix 256², TR=4.2, TE=1.5, flip 40°, keyhole percentage 40, resolution 1.6 x 1.6 mm, slice thickness 3-4 mm [zero-filled to 1.5-3 mm], SENSE factor 4, temporal resolution 3 sec, 15-20 phases), followed by SENSE three station automated moving table CE-MRA (33 cc Gd) [1]. Mask images for subtraction are obtained for both the keyhole and moving table CE-MRA. The keyhole series provides a combination of intermediate-resolution time-resolved arterial imaging and venous enhancement timing information over the entire calf. Using this data in conjunction with the aortic arrival time, transit time from aorta to a.) pedal arteries, and b.) peripheral veins (when it occurs) is easily measured. Based on this, appropriate resolution and SENSE factors for the moving table CE-MRA are quickly chosen (from pre-existing protocols) such that lower station acquisition (centric acquisition order) begins at least beyond the pedal arterial peak but still prior to calf venous enhancement. Sub-systolic (60 mm Hg) thigh venous compression cuffs (TopSpins Inc., Ann Arbor, MI) are inflated during Gd injection in cases where venous enhancement is seen earlier than lower station acquisition can be initiated. Typical true acquired resolution/scan time for the moving table CE-MRA is 1.2 x 2.1 x 2.6 mm³/5-8 sec, 1.2 x 2.1 x 2.0 mm³/5.5-10 sec, and 1.0 x 1.0 x 1.0 mm³/45-70 sec in the upper, middle, and lower stations respectively. The lower station coronal slab is thick enough (12 cm) to include the pedal arch.

Findings

Our prototype coil allowed SENSE factors up to 5 to be used at all 3 stations, with geometrical (g) factors at SENSE factor 5 ranging between 1.5 and 2 in the upper station and 1.25 and 1.5 in the middle and lower stations. Intrinsic SNR is approximately a factor of 2 greater than with conventional vendor supplied phased array coils.

Calf dynamic image quality is good, and unlike 2D MR DSA techniques [2] allows for visualization of veins (Figure 1). Moving table static CE-MRA image quality is routinely excellent at all stations, in part because spatial resolution is greater than typically achieved with other CE-MRA techniques (Fig 2). Even despite current table movement limitations of approximately 6 sec between stations, lower station acquisition can still begin as early as 23.5 sec post beginning upper station acquisition. Recent experience with two-station timing data from 56 vasculopathic patients undergoing peripheral MRA indicates greater than 85% would have no significant venous enhancement with these timing limitations and without venous compression. Despite requiring 3 separate injections, the protocol is easy to implement and has simplified the performance of moving table CE-MRA at this institution.

Discussion

We prefer the single injection moving table technique over two-injection variants due to the more efficient use of the contrast bolus over multiple stations. The biggest criticism of this technique is that lower station venous enhancement occurs more frequently. By accelerating upper and middle station acquisition while maintaining or increasing spatial resolution, however, the incidence of venous enhancement will undoubtedly decrease. Adding thigh venous compression, which has been shown to significantly slow venous arrival and decrease venous enhancement [2], will also help reduce this problem. While using SENSE factors as high as 5 in combination with high-resolution acquisition does lead to a loss in SNR (smaller voxels, less phase encodes, higher g factor), CE-MRA is typically abundant enough in SNR that this can be tolerated. In order to offset SNR loss, however, we suggest and use higher relaxivity contrast agents such as MultiHance (Gd-BOPTA, Bracco Diagnostics, Princeton, NJ).

Although the implementation is somewhat complex, a 3D dynamic lower extremity study is obtained for each patient, in part to evaluate differential or retrograde arterial filling (Figure 1) that might not be recognized on the high-resolution moving table dataset, and in part to help set up appropriate timing to avoid venous enhancement. In patients who exhibit no or delayed (>30-40 sec) calf venous enhancement, smaller SENSE factors and/or greater spatial resolution can be planned to slow upper and middle stations acquisitions (and increase SNR and resolution), as venous enhancement will not be an issue. In patients with rapid venous enhancement, thigh venous compression combined with higher SENSE factors and, if necessary, decreased resolution will minimize the delay prior to lower station acquisition. On the rare cases in which venous enhancement is still seen, we find the dynamic lower station angiogram usually adequate to visualize the arterial structures and help interpret the venous-contaminated high-resolution MRA. We have noted several patients in whom arterial transit from aorta to ankle is extremely slow (>40 seconds). Having this knowledge helps avoid imaging the lower station too early and seeing poor or non-existent pedal artery filling. Ongoing work with this new protocol will better determine how robustly it performs.

Bibliography

- 1.) Maki JH, Wilson GJ, Eubank WB, Pederson KM, Hoozeveen RM. Proceedings Thirteenth Scientific Meeting ISMRM, Miami Beach, FL (2005) 454.
- 2.) Zhang HL, Ho BY, Chao M et. al. AJR 183:1041-1047 (2004).

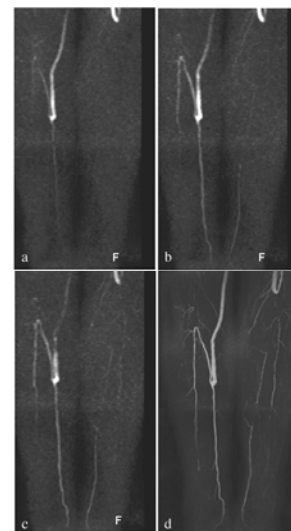


Figure 1. Three consecutive dynamic scans (a-c) and high-resolution lower station CE-MRA (d) showing retrograde flow up right posterior tibial artery distal to graft insertion.

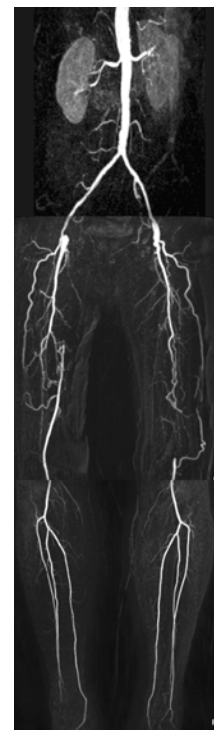


Figure 2. Single injection CE-MRA using prototype PV coil. SENSE factor 5 at all stations.