

## MRI Guided Prostate Interventions in 3T

A. Krieger<sup>1</sup>, P. Guion<sup>2</sup>, A. El-Sharkawy<sup>3</sup>, G. Metzger<sup>4</sup>, J. Coleman<sup>5</sup>, R. Grubb<sup>5</sup>, D. Qian<sup>6</sup>, A. Gharib<sup>7</sup>, D. Thomasson<sup>7</sup>, A. Singh<sup>2</sup>, G. Fichtinger<sup>6</sup>, L. L. Whitcomb<sup>1</sup>, C. Ménard<sup>2,8</sup>, E. Atalar<sup>6,9</sup>

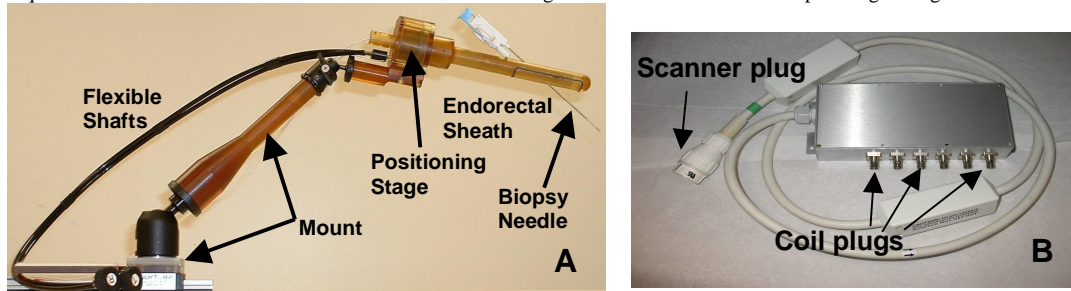
<sup>1</sup>Department of Mechanical Engineering, Johns Hopkins University, Baltimore, MD, United States, <sup>2</sup>Radiation Oncology Branch, National Cancer Institute, NIH-DHHS, Bethesda, MD, United States, <sup>3</sup>Department of Electrical and Computer Engineering, Johns Hopkins University, Baltimore, MD, United States, <sup>4</sup>Philips Medical Systems, Cleveland, OH, United States, <sup>5</sup>Urologic Oncology Branch, National Cancer Institute, NIH-DHHS, Bethesda, MD, United States, <sup>6</sup>Department of Radiology, Johns Hopkins University, Baltimore, MD, United States, <sup>7</sup>Diagnostic Radiology Department, Clinical Center, NIH-DHHS, Bethesda, MD, United States, <sup>8</sup>Department of Radiation Oncology, Princess Margeret Hospital, University of Toronto, Toronto, ON, Canada, <sup>9</sup>The Department of Electrical and Electronics Engineering, Bilkent University, Ankara, Turkey

### Introduction:

Earlier, we developed a system that enables image-guided prostate needle interventions in a conventional 1.5T MR scanner. This APT-MR system (Access to Prostate Tissue under MRI-guidance) provided transrectal needle access to the prostate while a patient was imaged inside a 'closed' 1.5T scanner and successfully combined tissue biopsy and fiducial marker placement with MR imaging in clinical trials [1]. The APT-MRI system consists of a remotely actuated manipulator [2], using active fiducial tracking [3], which allows for targeting of a needle with millimeter accuracy. The purpose of this work is to investigate the ability of the APT-MRI to work with a 3T Philips Intera MR system. The modified 3T APT-MRI system provides the potential for improved target selection by taking advantage of the improved sensitivity provided by the higher field strength for diagnostic imaging, MR spectroscopy, and dynamic contrast-enhanced magnetic resonance imaging (DCE-MRI).

### Materials/Methods:

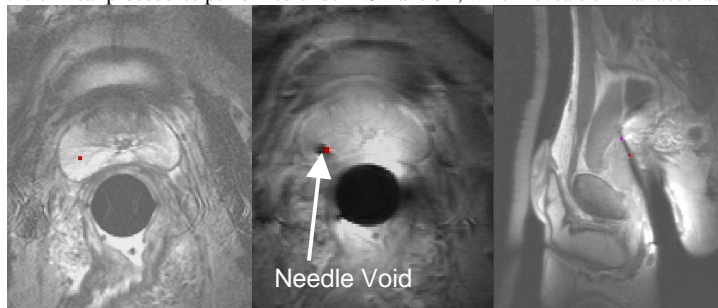
The challenges of moving the APT-MR system to a higher field strength scanner included the increased field inhomogeneities and the decrease in wave length and phase variations, which cause larger imaging artifacts from the metallic components of the manipulator and adverse effects on the tracking coils. As shown in Figure 1, the 3T APT-MR system is composed of a manipulator that enables transrectal insertion of a biopsy needle. Three tracking microcoils are integrated into the manipulator to encode its position during the intervention. An endorectal imaging coil provides anatomical images of the prostate and surrounding tissue. A software program provides real-time feedback to the operator. In addition to the endorectal coil, a large double-looped, phased array coil was constructed to improve the visibility of the surrounding structures. All coils operated as receivers and were actively decoupled from the body coil to ensure patient safety and high image quality. To interface the 6 coils of the system to the scanner, a box was built (Figure 1B) that contained both an RF board and a digital board. While the RF board serves as a low-noise preamplifier, the digital board functions as a coil identifier for the scanner and handles the decoupling control signals to switch the pin diodes used for decoupling. Pulse sequences were modified to enable accurate fast device tracking. DCE-MRI was used for the planning of target sites.



**Figure 1:** A. Picture of the APT-MR system showing the different components of the manipulator, the endorectal sheath, positioning stage, flexible actuation shafts, and mount with a biopsy needle from MRI Devices, Daum. B. The 6 channel interface box that connects all of the coils to the 3T Philips Intera scanner.

### Results:

After confirming both the electrical and mechanical safety of the device, it was approved by the Safety Subcommittee of the NMR center, and the clinical research protocol was approved by the IRB-NCI for human research. To date, four successful fiducial marker placement procedures with four implanted markers each have been performed in patients using the 3T APT-MRI system. Four successful clinical biopsy procedures were also performed, where four to six biopsy samples were obtained per patient. There have been no unexpected severe adverse events. Figure 2 shows an example of images obtained during one of the biopsy procedures, where a target is selected on an anatomical image and then the needle is guided to its target by remotely positioning the mechanical manipulator via the flexible actuation shafts with the aid of the tracking mechanism. The needle's position is then verified on both axial and sagittal images. Figure 3 shows a comparison of the targeting accuracy between the clinical procedures performed under 1.5T and 3T, which reveals similar accuracy values for the different field strengths.



**Figure 2:** Targeting and needle visualization images. A: A target (red dot) is selected on an axial TSE T2-weighted image. B: The needle tip void is visualized in an axial TSE Proton Density image. It can be seen that the desired target matches the actual position of the needle. C: The needle void is visualized on a sagittal TSE Proton Density image, where the estimated needle path (red and purple dots) matches the actual path.

### Conclusions:

We successfully adapted the APT-MRI system to conduct needle interventions for prostate cancer diagnosis and therapy under 3T MR image guidance. The system's performance has been verified in eight clinical procedures. Targeting accuracies of the procedures performed under 3T were comparable to the accuracies of the procedures under 1.5T, which confirms that safe and accurate needle placement can be performed with the APT-MRI system under 3T. Further work is being conducted to take advantage of the higher field by including MR spectroscopy and DCE-MRI for the selection of target sites.

### Acknowledgment:

The authors would like to thank Philips Medical Systems, Cleveland, OH, USA, for their technical support.

### References:

[1] Susil RC ISMRM, Kyoto, 2004;381. [2] Krieger A. Trans on Biomed Eng, In Press. [3] Dumoulin CL. Magn Reson Med, 1993;29:411.

	1.5 Tesla	3 Tesla
Biopsy needle placement error	2.8mm	3.8mm
Marker placement error	6.5mm	7.4mm

**Figure 3:** Comparison of targeting accuracy of clinical procedures under 1.5T and 3T. The table shows mean biopsy needle placement errors for 6 procedures under 1.5T and 4 procedures under 3T, and marker placement errors for 10 procedures under 1.5T and 4 procedures under 3T.