

The Incidental Magnetization Transfer Effect in Multislice Imaging At 3.0T

Y. Chang^{1,2}, M-J. Hwang², S-J. Bae², J-J. Lee², I-S. Kim², Y-J. Lee², J-A. Park², B-H. Park², S-G. Woo³, C-H. Shon³

¹Department of Diagnostic Radiology, Kyungpook National University, Daegu, Korea, Republic of, ²Department of Medical and Biological Engineering, Kyungpook National University, Daegu, Korea, Republic of, ³Department of Diagnostic Radiology, Dongsan Medical Center, Keimyung University, Daegu, Korea, Republic of

Introduction

Incidental magnetization transfer (MT) effect, which is a source of signal reduction in conventional multi-slice imaging, has been observed in brain and muscle at 1.5T [1]. The incidental MT effect is more dramatic in fast spin-echo (FSE) imaging which employs up to 32 times as many RF pulses per slice in the TR interval. Currently, no data are available for incidental MT effect at higher magnetic field. In this study, we investigate the incidental MT effect in multi-slice FSE imaging of human brain at 3.0T.

Material and Methods

Ten normal subjects (2 males, 1 females; age: 24-26 years; mean age: 25 years) with no history of neurological abnormalities were included in this study. All subjects provided written informed consent in accordance with protocols approved by the institutional review board. All experiments were performed at 3.0T (GE VH3M4) and at 1.5T (GE Signa 9.1M4) MR scanner using standard head coil. The MR images were obtained using a FSE sequence consisting of a 16-echo pulse train. No off-resonance MT pulses were applied. The scan parameters were : TR/TE = 2500 msec/ 98 msec (3.0T) and 105.5 msec (1.5T), slice thickness = 5 mm, slice gap = 2.5 mm, matrix size = 256x192, bandwidth = 15.6 KHz and varying the number of slices from 1 to 9. The incidental MT effect in multi-slice imaging was measured by comparing image signal intensities for a single slice and the central slice of a 3-, 5-, 7-, 9-slice images. The MT ratio (MTR), which is defined as $(S_0 - S_i)/S_0$, is calculated at various regions of brain. In MTR, S_0 is signal intensity of single slice image and S_i is the signal intensity of the same anatomical location in multi-slice images.

Results

Comparison of incidental MT effect between 1.5T and 3.0T: Figure 1(WM) and 2(GM) show the MTR values for two regions of the brain, including white matter (WM), deep gray matter (GM). Both anatomic structures of brain show higher MTR values at 3.0T when compared to the values at 1.5T. That is, the incidental MTR increased from 33% at 1.5T to 45.8% at 3.0T in case of 9 slice image of genu part of corpus callosum. The difference of incidental MT effect between 1.5T and 3.0T is more significant in WM than in GM. Also our data revealed that the incidental MT effect increases as the number of slices increased. However, as shown in Figure 1 and 2, the incidental MT effects became saturated for GM even at 9 slices whereas the WM showed less saturation at 9 slices.

Incidental MT effect at different anatomical locations: Among brain regions, corpus callosum shows the highest incidental MTR values and in general MT effect appears more pronounced in white matter than in gray matter at 3.0T(Figure 3). All anatomical locations showed higher incidental MTR as the slice number increased. The least incidental MT effect was observed in CSF. The same behavior of incidental MT effect on anatomical locations was observed at 1.5T although the difference in incidental MTR among anatomical structures was smaller.

Discussion

Magnetization transfer contrast is traditionally obtained using an extra long off-resonance RF pulse. However, in previous studies, it has been observed that conventional multi-slice image signal intensity of biological tissues can be reduced and it has been proposed that this may be due to magnetization transfer effect [2]. This incidental MT effect provides therefore a mechanism for multi-slice interference. The reported data on the incidental MT effect were obtained at 1.5 T scanner. Since MT is field-dependent phenomenon and recently 3.0T MR scanner became available at clinical setting, we tried to measure the incidental MT effect at 3.0T. As shown in Result, the incidental MT contrast was higher at 3.0T for all anatomical locations. Therefore, MR image contrast of multi-slice imaging can be more affected by incidental MT effect at higher magnetic field. The clinical implication of this finding need to be valuated in the near future. Another conclusion from our study is that quantitative relaxation measurement or fat fraction from multi-slice images is inadvisable due to incidental MT effect. That is, MR signal intensity, which is strongly affected by MT effect in multi-slice imaging at higher field will have a chance to mislead the result of the relaxation time or fat fraction measurement.

References

- [1] Dixon WT, Engels H, Castillo M et al. *MRI* 8 (1990) pp. 417-422
- [2] Santyr G. *MRI* 11 (1993) pp. 521-532

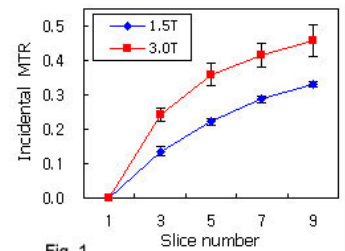


Fig. 1

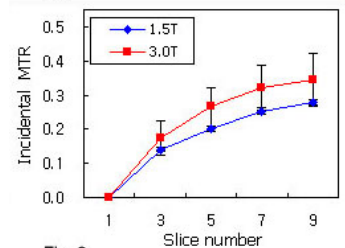


Fig. 2

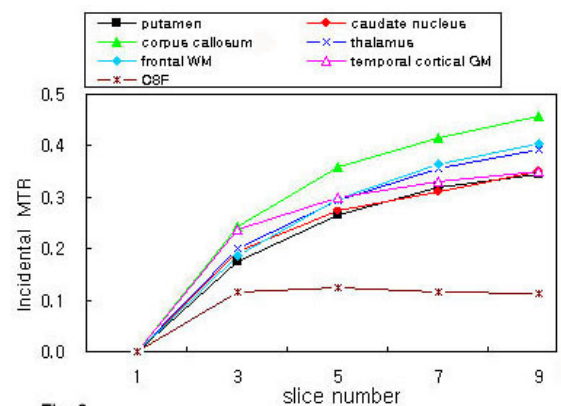


Fig. 3