

### 3D MRSI of Brain Tumors at 3 Tesla using an 8 Channel Phased Array Head Coil

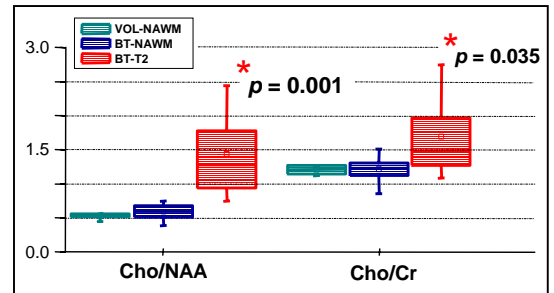
J. A. Osorio<sup>1,2</sup>, E. Ozturk<sup>1,2</sup>, S. Cha<sup>1</sup>, S. Chang<sup>3</sup>, M. S. Berger<sup>3</sup>, D. B. Vigneron<sup>1,2</sup>, S. J. Nelson<sup>1,2</sup>

<sup>1</sup>Department of Radiology, University of California, San Francisco, CA, United States, <sup>2</sup>UCSF/UCB Joint Graduate Group in Bioengineering, University of California, San Francisco, CA, United States, <sup>3</sup>Department of Neurological Surgery, University of California, San Francisco, CA, United States

**Introduction:** Despite the widespread clinical use of MR imaging in brain tumor evaluation, there are circumstances when interpretation of the images is complicated by the difficulties in identifying the true extent of the lesion and in distinguishing treatment effects from tumor progression [1]. This has led to a greater demand for alternative imaging techniques such as MR Spectroscopic Imaging (MRSI), which reflect physiologic rather than morphologic properties of the tissue. With MR systems having the advantage of moving to higher fields, such as 3T, there is an increased capability of better characterizing tumor tissue with the improved signal to noise (SNR) and spectral resolution. The use of phased array coils has also proven to be advantageous in that they can provide higher sensitivity over that from a standard head coil. However, the effect of magnetic susceptibility artifacts and B1 inhomogeneity increases with field strength [2]. The goal of this study was to implement MRSI at 3T for brain tumor patients using an 8 channel phased array coil.

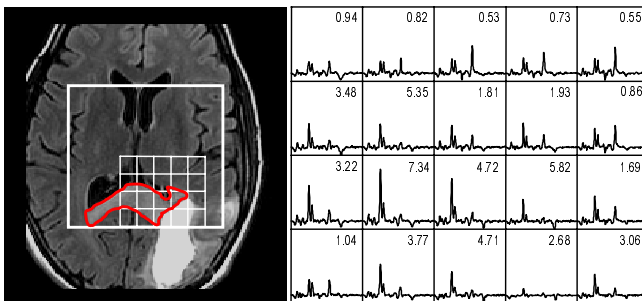
**Methods:** Forty-two MRI/MRSI examinations were performed on 33 patients (21M/12F; 25-67 years) with histologically confirmed brain tumors: 29 glial tumors (8 Grade II, 8 Grade III, 13 Grade IV), and 4 non-glial tumors. Each patient received MRSI exams on a 3T GE Signa EXCITE scanner using body coil excitation and reception with an 8 channel phased array head coil. T2-weighted FLAIR, pre- and post-contrast T1-weighted 3D SPGR images were acquired and used to exclude regions of T2-hyperintensity and normal appearing white matter (NAWM) for further analysis. Proton density weighted GRE images were acquired using the manufacturer provided parallel imaging calibration sequence in order to estimate coil sensitivity profiles. The 3D MRSI data were acquired with 3D chemical shift imaging (3D-CSI), point resolved spectroscopic (PRESS) volume localization, very selective suppression (VSS) pulses, and chemical shift selective saturation (CHESS) water suppression in 17 minutes with TR/TE = 1100/144ms. Spectral array sizes were 16x16x8 acquired elliptical k-space sampling with fields of view corresponding to a nominal spatial resolution of 1cc [1]. The spectral arrays from the 8 channel phased array coil were each analyzed individually and the signals were combined using in-house software that weights the data by their coil sensitivities. Data were apodized in the time domain using a 4Hz Lorentzian exponential. Seven volunteers were also scanned using the same parameters described above. In patients, regions of T2-hyperintensity were manually contoured using the T2-weighted FLAIR image. Pre-contrast T1-weighted 3D SPGR images were used for segmentation of white matter (WM) using a Markov random field model. The regions of T2-hyperintensity were then subtracted from the WM segmentations to produce a NAWM map. The resulting maps were regrided to yield the fraction of each spectroscopic voxel that was deemed NAWM,  $f_{NAWM}$ , or T2-hyperintense,  $f_{T2}$ . All voxels in which  $f_{NAWM} < 0.9$  or where  $f_{T2} < 0.7$  were excluded from further analysis. The remaining mean metabolite peak height values within voxels of NAWM and T2-hyperintensity regions were then used to calculate regional metabolic ratios. Signal to noise ratios (SNRs) were also calculated within these regions using the mean standard deviation of the noise from the right end of the spectra within the PRESS volume.

**Results:** Both patient and volunteer data demonstrated that good quality MRSI data could be obtained consistently using the 8 channel phased array coil at 3T. The mean SNR values for choline (Cho) and n-acetyl aspartate (NAA) within NAWM regions were  $42.0 \pm 7.8$  and  $80.0 \pm 11.1$  (mean  $\pm$  s.d.) for normal volunteers, respectively. These values were comparable to regions of NAWM for patients where Cho and NAA had SNR values of  $42.2 \pm 11.6$  and  $71.9 \pm 14.2$ . These SNR values verified the reproducibility of the spectra within patient acquisitions and were approximately twice as high as values that we had observed in our previous brain tumor studies that were performed at 1.5T with a volume head coil [1]. The mean Cho/NAA was similar between volunteers ( $0.5 \pm 0.04$ ) and patients ( $0.6 \pm 0.1$ ,  $p=0.15$ ). The same ratio was significantly higher in regions of T2-hyperintensity relative to volunteer NAWM for patients ( $1.4 \pm 0.7$ ,  $p=0.001$ ) as shown in Figure 1. This difference demonstrates the ability of 3D MRSI to distinguish tumor from normal tissue at 3T. Figure 2 shows an example of spectra array using 8 channel phased array coil for a patient with Grade IV tumor after surgery. Figure 3 shows representative normal (A) and metabolically abnormal (B) spectra voxels from the same patient in Figure 2. As shown in Figure 3, there was a marked increase Cho/NAA within the metabolically abnormal voxel relative to normal tissue.

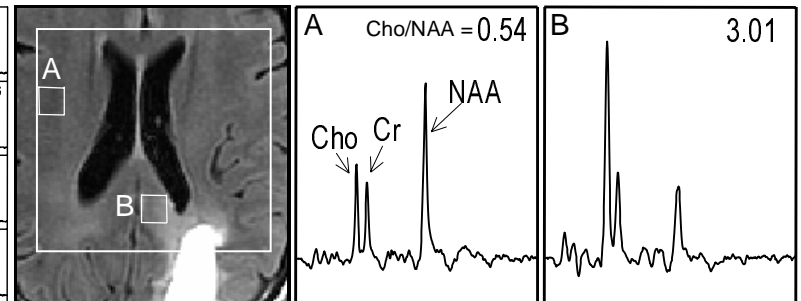


**Figure 1.** Metabolite mean height ratios for volunteers and brain tumor (BT) patients. Note the statistical difference within regions of T2-hyperintensity relative to volunteer NAWM.

**Discussion and Conclusion:** This study demonstrated clinically acceptable 3D MRSI for brain tumor patients using an 8 channel phased array coil at 3T. It was observed that the Cho/NAA and Cho/Cr were significantly increased in the T2-hyperintense regions relative to NAWM. The wide distribution of metabolite ratios within the T2-hyperintense region may indicate heterogeneity of tumor grades.



**Figure 2.** 3D <sup>1</sup>H MRSI using an 8 channel phased array coil at 3T from a grade IV post-surgical tumor patient. Note the metabolically active tumor tissue within the corpus callosum. T2 contour used is in red.



**Figure 3.** Same patient as in Figure 2, slice is 10mm above. Voxels chosen are from regions of normal and abnormal tissue.

**Acknowledgments:** This research was supported by NIH grant P50 CA97257, LSIT 01-10107, and NIGMS grant R25 GM56847.

#### References

1. Nelson SJ, et al. *Magn. Reson. in Med.* 2001; 46:228-229.
2. Frayne R, et al. *Invest. Radiol.* 2003; 38(7):385-402.