

## Dynamic Contrast Enhanced and Diffusion MRI show rapid and dramatic changes in tumor microenvironment in response to inhibition of HIF-1 $\alpha$ using PX-478

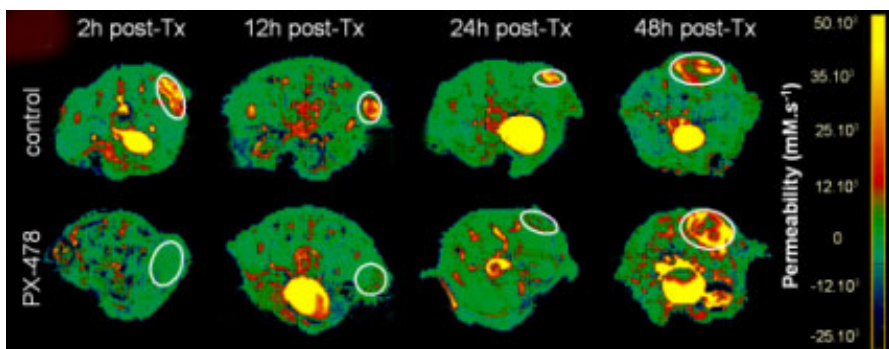
B. F. Jordan<sup>1,2</sup>, M. Runquist<sup>3</sup>, N. Raghunand<sup>1</sup>, I. Robey<sup>1</sup>, C. Howison<sup>3</sup>, A. Baker<sup>4</sup>, R. Williams<sup>4</sup>, L. Kirkpartick<sup>5</sup>, G. Powis<sup>4</sup>, R. J. Gillies<sup>1</sup>

<sup>1</sup>Biochemistry, University of Arizona, Tucson, AZ, United States, <sup>2</sup>Biomedical Magnetic Resonance, Université Catholique de Louvain, Brussels, Belgium, <sup>3</sup>Biotechnology, University of Arizona, Tucson, AZ, United States, <sup>4</sup>Cancer Center, University of Arizona, Tucson, AZ, United States, <sup>5</sup>Prolx pharmaceuticals, Tucson, AZ, United States

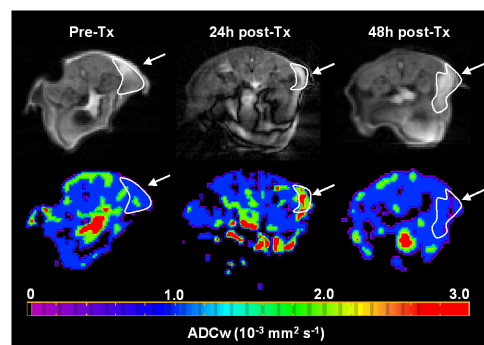
**Introduction:** Solid tumors with areas of hypoxia are the most aggressive and difficult tumors to treat [1]. The cancer cell response to hypoxia is mediated through the hypoxia inducible factor-1 (HIF-1) transcription factor [2]. Clinically, HIF-1 $\alpha$  over-expression has been shown to be a marker of highly aggressive disease and has been associated with poor prognosis and treatment failure in a number of human cancers [2]. **PX-478** is a novel agent that suppresses both constitutive and hypoxia-induced levels of HIF-1 $\alpha$  in cancer cells [3]. The inhibition of tumor growth by **PX-478** is positively associated with HIF-1 $\alpha$  levels in a variety of human tumor xenografts in *SCID* mice. This study monitored the antitumor activity of PX-478 prior to phase I/II clinical trials, on HT-29 human colon xenografts using both dynamic contrast-enhanced, DCE, MRI with a macromolecular contrast reagent and diffusion-MRI and to assess the use of these as early and quantitative biomarkers for tumor response.

**Methods:** *SCID* Mice bearing HT-29 colon xenografts were treated with either vehicle or with 125 mg/kg PX-478 (Prolx Pharmaceuticals) and imaged over time. Bioluminescent images were obtained using a cryocooled CCD (Roper Scientific) of tumors expressing firefly luciferase under regulation of a CMV promoter (control) or the Hypoxia Response element (HRE) from the VEGF promoter region. All imaging was performed on a 4.7 T bore MR imager (Bruker, Billerica, MA). A diffusion-weighted series was obtained using DIFRAD radial acquisition [4], with TR=2s, TE=36ms,  $\Delta$ =13 ms,  $\delta$ =5ms. Images were reconstructed using a filtered back projection of magnitude data. ADC<sub>w</sub> maps were generated by fitting 3 b-values to the Stejskal-Tanner equation. Next, proton density and a series of SE images (TR=300ms, TE=5.9ms, NA=4, NR=23) were collected over 60 minutes, with the contrast reagent solution (Gd-BSA, 0.6 mg/g) being injected i.v. during repetitions 2-5. Signal enhancement was converted to [albumin-Gd-DTPA] vs time data and this was fitted to a straight line for each pixel, to obtain a slope (related to vascular permeability) and y-axis intercept (related to the vascular volume fraction). Maps of vascular permeability and vascular volume fraction were generated. All animal protocols were approved by the University of Arizona Institutional Animal Care and Use Committee.

**Results:** PX-478 caused an inhibition of HIF-1 $\alpha$  I, as evidenced by ex vivo immunocytochemistry and a decrease in bioluminescence of HRE-driven luciferase, relative to controls. With MRI, PX-478 induced a dramatic and significant reduction in tumor blood vessel permeability within two hours after treatment. Mean reductions of 73.3  $\pm$  13.9%, 72.4  $\pm$  6.9% and 55.0%  $\pm$  10.3% were observed at 2, 12, and 24h, respectively. The effect of PX-478 on permeabilities returned to baseline by 48 hours (Fig.1). Histograms of these changes showed a broad range of permeabilities in control tumors, and a homogeneous distribution centered about low values in treated animals. PX-478 had no effect on the tumor vascular volume fraction. The Anti-VEGF antibody Avastin<sup>TM</sup> (positive control) reduced both the permeability and the vascular volume. In contrast, PX-478 had no effect on the perfusion behavior of a drug-resistant tumor system, A549 (negative control). Although not affected at early time points, tumor cellularity, estimated from the ADC, was significantly decreased 24h and 36h after treatment (+94.5 $\pm$ 4.8% and +38.4 $\pm$ 4.9%, respectively), before returning to control values by 48 h. Immunocytochemistry (ICC) showed rapid reductions in both tumor HIF-1 $\alpha$  and vascular endothelial growth factor, VEGF, both of which returned to pre-treatment values by 6 and 12 hours, respectively.



**Fig.1 Permeability maps:** Axial slices of mice treated with PX-478 or vehicle control. At time points. Tumors are encircled.



**Fig.2 Diffusion maps and DW images (b=25)** Before and 24, and 48h post-Tx

**Conclusions:** The diffusion experiments showed the earliest significant response of ADC to therapy yet reported. Although it was a later response, the dynamic range for the ADC response was greater than that of permeability. The combination of the two techniques gives unique insights into the complex response of HT-29 tumors to PX-478 by showing very early decreases in vascular permeability followed by large reductions in cellularity. Mechanistically, the time course of the perfusion changes followed reductions in tumor HIF-1 $\alpha$ , measured *in vivo* with bioluminescence and ex vivo with ICC. The permeability changes did not correlate to tumor or systemic VEGF levels, suggesting that other factors may be responsible for the changes in blood vessel permeability. Interestingly, the lack of response by A-549 tumors indicates that the effect of PX-478 on permeability is mediated via the tumor, and not the host. Based on these pre-clinical findings, both of these imaging endpoints will be included in the phase I/II clinical trial of PX-478.

**References:** [1] Hoeckel M, et al., (1996). *Cancer Res* 56, 4509-4515; [2] Semenza GL (2000). *J Amer Phys Soc* 88:1474-1480; [3] Welsh S, et al., (2004). *Mol Cancer Ther* 3(3), 233-44; [4] Trouard TP et al., *Magn Reson Med.* (1999); 42(1):11-8.