

# High-Resolution Renal MRA: Comparison of Image Quality and Vessel Depiction with Different Parallel Imaging Acceleration Factors

H. J. Michaely<sup>1,2</sup>, K. A. Herrmann<sup>1</sup>, H. Kramer<sup>1</sup>, O. Dietrich<sup>1</sup>, G. Laub<sup>3</sup>, M. F. Reiser<sup>1</sup>, S. O. Schoenberg<sup>1</sup>

<sup>1</sup>Institute of Clinical Radiology, University of Munich, Munich, Bavaria, Germany, <sup>2</sup>Department of Radiology, UCLA, Los Angeles, California, United States, <sup>3</sup>Siemens Medical Systems, Malvern, PA, United States

## Purpose

To investigate the image quality and the vessel depiction of renal MRA with integrated parallel imaging techniques (iPAT) using acceleration factors of 2 and 3.

## Material and Methods

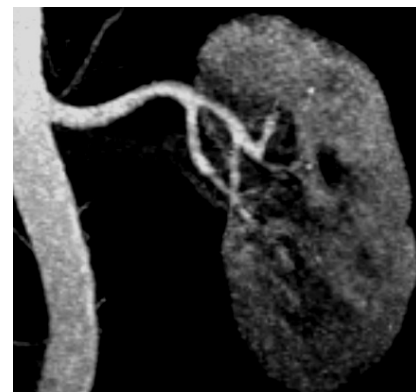
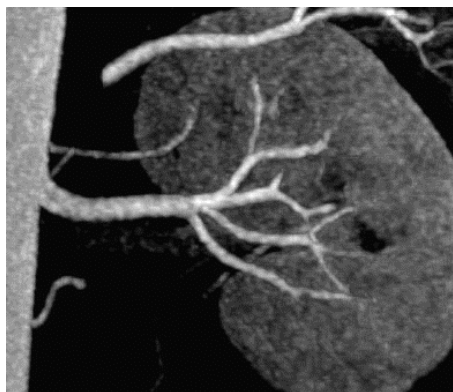
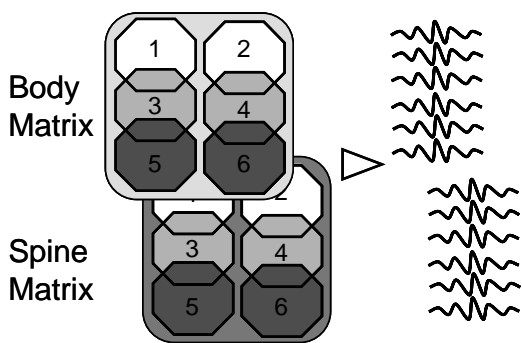
In this prospective study renal MRA of 14 patients (3 women, 14 men, 24 renal arteries) was performed with an acceleration factor of 3. 12 patients (7 women, 5 men, 21 renal arteries) underwent renal MRA with an acceleration factor of 2. For the MRA a 3D-GRE sequence with an acquired spatial resolution of  $0.9 \times 0.8 \times 1.0 \text{ mm}^3$  was applied (TR/TE=3.79ms/1.39ms, FOV 400mmx320mm, partitions per slab=80, Matrix=512x384, flip angle=25°, Bandwidth 350 Hz/Pixel, 6/8 partial phase Fourier) on a 32-channel 1.5T MR-scanner (Magnetom AVANTO 32x76, Siemens Medical Systems) with a gradient strength of 45mT/m and slew rate of 200mT/m/ms. Acquisition time was 26s with iPAT 2 and 19s with iPAT3. GRAPPA [1] was used as reconstruction algorithm. All parameters other than acquisition time and acceleration factor were kept constant. Patients received 15ml of a 1-molar contrast agent (gadobutrol, Gadovist, Schering) at 2ml/sec followed by a 20ml saline flush. A testbolus technique was used for the bolus timing. One body matrix and two clusters of the spine matrix were used for signal reception. For iPAT 2 the coils were run in the *dual mode* with 8 independent signals, for iPAT 3 in the *triple mode* with 12 independent signals (Figure 1). Due to the non-uniform distribution of noise with the use of parallel imaging, the signal-to-noise ratio (SNR) was assessed using repetitive phantom measurements using identical sequences with iPAT 2 and 3 respectively. The images were rated by two radiologists regarding noise, artifacts and the quality of vessel depiction for the proximal, segmental and subsegmental renal artery on a three point rating scale. A Mann-Whitney-U test was applied to compare the ordinal data from the reading. To evaluate the interreader agreement, kappa statistics were applied. The SNR was determined by measuring mean signal intensity and standard deviation. For statistical comparison of the SNR a t-test was applied.

## Results

The phantom measurements showed a significant decrease in SNR from 11.96 to 9.13. However both readers found no increase in the patient's image noise but significant reduction of artifacts from breathing and motion with iPAT 3. No reconstruction artifacts were seen. The proximal part of the renal arteries was equally well seen with both techniques (Figure 1 and 2). The depiction of segmental vessels was rated significantly better by both readers with iPAT 3, the subsegmental vessels were rated significantly better by one reader only. iPAT 3 also resulted in a better interreader agreement for the segmental parts of the renal arteries (k: 0.51 (iPAT 2), k: 0.86 (iPAT 3)).

## Conclusion

The use of iPAT 3 for renal MRA enables a better depiction of the distal parts of the renal artery. The improved visibility leads to a better interreader agreement and thus higher diagnostic certainty. The decrease in SNR is counterbalanced by a significantly decreased number of artifacts.



**Figure 1**

Scheme of the coils in the triple mode. The signal of each single element is fed into an independent receive channel.

**Figure 2**

Renal MRA with iPAT 3: the renal arteries can be clearly followed to the third branching.

**Figure 3**

Renal MRA with iPAT 2: the renal arteries can only be well seen in the proximal part.

1. Griswold, M.A., et al., *Generalized autocalibrating partially parallel acquisitions (GRAPPA)*. Magn Reson Med, 2002. 47(6): p. 1202-10.