

EOG measurement during EPI data acquisition for the event related fMRI of the voluntary eye blinking

H. Yoon¹, M-S. Song¹, J-Y. Chung², H. Park²

¹fMRI lab, KAIST, Daejeon, Daejeon, Korea, Republic of, ²electrical engineering, KAIST, Daejeon, Daejeon, Korea, Republic of

Abstract

The electrooculogram (EOG) of voluntary eye blinking is a distinguishable one among other eye blinking types such as spontaneous or reflexive blinking. In our study, we aimed to measure/detect the EOG of voluntary blinking during Echo Planar Imaging in the MR scanner. After the pulse artifact removal in the EOG signal, the waveform of EOG can clearly show voluntary eye blinking and this was equivalent to those measured at the outside of the MRI scanner. On the basis of this detection, each blinking event can be used as the temporal cue for the event related fMRI. In the results of the brain activation pattern, the activations of bilateral parahippocampal, precentral gyrus and right supplementary motor area were observed. According to this result, we would suggest that the precentral gyrus is important for voluntary blinking, rather than parietal area, as the previous studies suggested.

Introduction

With help of recent functional imaging techniques such as fMRI or PET, the neural mechanisms of adult humans during the eye blinking, especially voluntary eye blinking can now be investigated (Kato & Miyauchi, 2003). In one of the previous studies of voluntary eye blinking using fMRI, the activation regions are observed in the wide portion of frontal gyrus and posterior parietal cortex (Bodis-Wollner et al., 1999). Another previous study of Kato & Miyauchi (2003) indicated that the precentral gyrus was responsible for control of voluntary eye blinking. The majority of the studies involving human eye blink used reflectance of infrared light to measure eyelid responses. However, the method using EOG (electrooculogram) is suitable to be simultaneously measured during functional imaging in the MR scanner for measuring/detecting the activity of eyelids, because the electronic components involved in the infrared measurement interfere with imaging in the MRI environment.

Methods

Seven male and five female right-handed subjects (mean age: 22 years, S.D. 1.5 years) with normal or corrected-to-normal vision participated in the study. During this period they were instructed not to blink their eyes as long as the fixation point is shown. After the presentation of a fixation point for 20, 25, or 30 seconds, this fixation point was disappeared for 500 ms, in which the subjects should blink their eyes voluntarily. This presentation pattern was repeated 15 times for each subject. The interstimulus interval of 20, 25, and 30 seconds was repeated randomly. Total duration time of an experimental run was 6 minutes and 27.5 seconds for each subject. An fMRI-compatible electroencephalogram recording system, BrainAmp-MR (Brain Products GmbH, Munich, Germany) with a specially designed electrode cap (BrainCap-MR), was used for eye blink detection and recording during the MR imaging. Before the starting scanning session, we recorded subject's EOG waveform as reference data. This measurement included their amplitude, shapes, and rates in order to detect the eye blinking. During the functional MR imaging, the switching of gradient magnetic field induced severe artifacts on EOG waveforms whose amplitudes were 10 to 100 times larger than that of the EOG signal measured at the outside of the MR room. This made the monitoring of EOG waveforms difficult when MR imaging was being simultaneously performed. The artifact correction was done using commercially available software Vision Analyzer (Brain Products GmbH, Munich, Germany). Artifact was reduced by subtracting an averaged artifact waveform, followed by adaptive noise cancellation to reduce any residual artifact. After removing gradient-field induced artifacts on recording EOG, the eye-blinking signal can be clearly shown. This looks similar to those with each subject's reference EOG signal measured at the outside of the MR scanner (Figure 1). This waveform has over 150µV and about 2~4 Hz frequency. With this information, every blinking event of each subject can be recognized. Images were acquired by using 3 Tesla MRI scanner (ISOL Technology, Korea) with a quadrature head coil. Following a T1-weighted scout image, high-resolution anatomic images were acquired using an MPRAGE (Magnetization-Prepared RApid Gradient Echo) sequence with TR = 8.1 ms, TE = 3.7 ms, flip angle = 8°, and image size of 256 x 256. T2*-weighted functional data were acquired by using echo planar imaging (EPI) with TE = 37 ms, flip angle = 70°, TR = 2500 ms, and image size of 64 x 64. We obtained 30 slices of EPI images with slice thickness of 5 mm and no gaps between slices for the whole brain. Image data were analyzed using SPM99 (Wellcome Department of Cognitive Neurology, London). The events of voluntary blinking were consequently modeled (event-related design) using a canonical hemodynamic response and its temporal derivative. Planned comparisons were computed as contrasts for individual participants. The resulting contrast images were then used in random effect analyses at the group level. Activations were reported if they exceeded a threshold $P < 0.001$ (uncorrected at the single voxel level).

Results and Discussion

The recorded voluntary blinking events with EOG were the temporal cue for the data analysis regardless of experimental design. Cerebral activation pattern of the condition of voluntary blinking was observed in the bilateral hippocampal gyrus (BA 28), medial frontal gyrus (BA 6), and left hemispheric middle frontal gyrus (BA 8). EOG as a recording system allows for detection of eye blink during echo planar imaging, which is equivalent to eye blink detection in conditioning experiments at the outside of the magnet. A nonferrous ribbon cable, eliminating any loops, minimizes the artifacts. In the results of the imaging data, we could observe a precentral gyrus activation among others. This might be very interesting, since this can confirm the hypothesis that this area is responsible for the voluntary eye blinking, rather than parietal area.

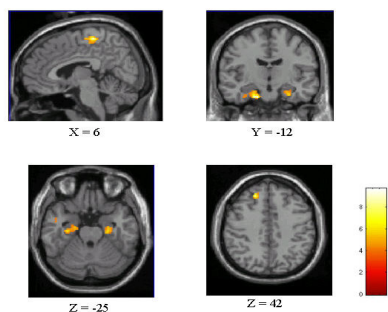


Fig.1. Map of activation area for voluntary blinking ($p < 0.005$, uncorrected on single voxel level).

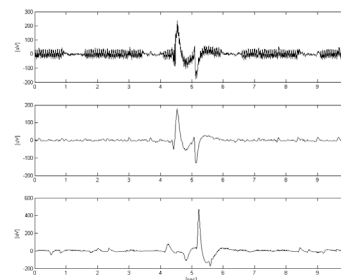


Fig.2 . The waveforms of EOG for voluntary blinking of one subject. Top: voluntary blinking waveform during the acquisition of EPI pulse. Middle: waveform after the pulse artifact correction. Bottom: waveform of voluntary blinking measured at the outside of the magnet. The total three waveforms have different scale of the amplitudes.

References

- Kato M, Miyauchi S. Functional MRI of brain activation evoked by intentional eye blinking. *NeuroImage* 2003; 18:749-759.
 - Bodis-Wollner I, Bucher SF, Seelos KC. Cortical activation patterns during voluntary blinks and voluntary saccades. *Neurology* 1999; 53:1800-1805.
- This work was partly supported by MOST (Korean Ministry of Science and Technology) with grant no. M1041300002-04N1300-00210.