

Flow Targeted Coronary MR Angiography: Comparison of Three Different Spin Labeling Techniques

M. Katoh^{1,2}, R. M. Botnar², A. Buecker¹, W. J. Manning², R. W. Guenther¹, M. Stuber³, E. Spuentrup¹

¹Department of Diagnostic Radiology, RWTH Aachen University Hospital, Aachen, Germany, ²Department of Medicine (Cardiovascular Division), Beth Israel Deaconess Medical Center and Harvard Medical School, Boston, MA, United States, ³Department of Radiology, Division of MRI Research, Johns Hopkins University Medical School, Baltimore, MD, United States

Introduction

Most of the currently available coronary MRA techniques have in common that they provide good anatomical but only limited blood flow information. To overcome this drawback, spin labeling projection coronary MRA (*ProjSSFP*) has been implemented, which provides both anatomical and blood flow information¹. This technique, however, requires the acquisition of two data sets and may lead to subtraction artifacts. Subsequently, a coronary MRA approach using a local re-inversion pre-pulse (*LoReInSSFP*) has been introduced². Hereby a 2D selective inversion pulse immediately follows a non-selective inversion pulse and re-inverts the magnetization of the blood in the ascending aorta. Similar to *ProjSSFP*, labeled aortic blood enters into the coronary arteries during an inversion delay, T1, allowing for selective visualization of the coronary arteries. This approach does not require the acquisition of a second data set and thus allows for a two-fold scan time reduction. However, blood SNR is decreased due to the use of two inversion pre-pulses that lower the available Mz magnetization. In addition, the choice of the inversion delay is limited for both *ProjSSFP* and *LoReInSSFP* coronary MRA approaches since the inversion pre-pulse is most effective if executed after aortic valve closure.

To address those issues, we have implemented another spin labeling coronary MRA approach based on a single inversion pre-pulse (*InflowSSFP*), which requires only one data set. In this study, we have compared all three approaches to evaluate the assets and drawbacks of each technique.

Materials and Methods

Coronary MRA of the right coronary artery was performed in ten healthy volunteers (5 men, 5 women, mean age 33 ± 11 years) on a 1.5 Tesla MR system (Gyroscan ACS-NT, Philips Medical Systems, Best, NL). A 3D radial SSFP coronary MRA sequence (TR/TE 6.3/3.2 ms, FA 120°, TFE factor 20, acquisition window 126 ms, FOV 360 mm², matrix 384 radial trajectories, spatial resolution 0.9 x 0.9 x 3.0 mm³) combined with three different spin labeling schemes was used:

Projection SSFP (ProjSSFP)

Two data sets, one with and one without the use of a 2D selective inversion (labeling) pre-pulse were acquired. Magnetization of the blood in the ascending aorta was inverted if the 2D selective pre-pulse was present. During the inversion delay (aortic valve closure – mid-diastole), labeled aortic blood enters into the coronary arteries. Subtraction of the two data sets then provides selective visualization of the coronary arteries.

Local Re-Inversion SSFP (LoReInSSFP)

One data set using a double-inversion pre-pulse (a non-selective inversion pulse immediately followed by a 2D selective inversion pulse; the latter re-inverts the magnetization of the blood in the ascending aorta) was acquired. During the inversion delay (aortic valve closure – mid-diastole), the re-inverted aortic blood enters into the coronary arteries allowing for selective visualization of the coronary arteries, while the remaining tissue is signal suppressed.

Local Inversion Inflow SSFP (InflowSSFP)

A slice-selective inversion pre-pulse positioned along the main axis of the coronary artery was applied for suppression of signal from coronary blood and the adjacent tissues. During a user defined inversion delay (e.g. early systole – mid-diastole), unsaturated blood from the ascending aorta enters into the inversion volume (i.e. coronary artery) allowing for visualization of the proximal and mid coronary arteries.

SNR of the coronary arteries, CNR between the coronary arteries and the epicardial fat, vessel length and vessel sharpness were analyzed.

Results

Spin labeling based bright-blood coronary MRAs providing blood flow information were successfully obtained in all subjects. Both *ProjSSFP* (Fig. 1a) and *LoReInSSFP* (Fig. 1b) allowed for selective visualization of the coronary arteries with excellent background suppression. Scan time was doubled in *ProjSSFP* due to the need for two data sets. In *InflowSSFP* (Fig. 1c), only tissue included in the inversion volume was signal suppressed. *ProjSSFP* and *InflowSSFP* yielded significantly increased SNR (Proj: 26 ± 12, LoReIn: 12 ± 5, Inflow: 28 ± 5; p < 0.05) and CNR (Proj: 22 ± 12, LoReIn: 10 ± 6, Inflow: 25 ± 5; p < 0.05) compared to *LoReInSSFP*. Comparable vessel length was found with all sequences (Proj: 70 ± 18, LoReIn: 62 ± 18, Inflow: 73 ± 18; n.s.) while vessel sharpness was best in *InflowSSFP* (Proj: 59 ± 12, LoReIn: 54 ± 12, Inflow: 68 ± 5; p < 0.05). Constantly good image quality was achieved using *InflowSSFP* likely due to the simple planning procedure and short scanning time.

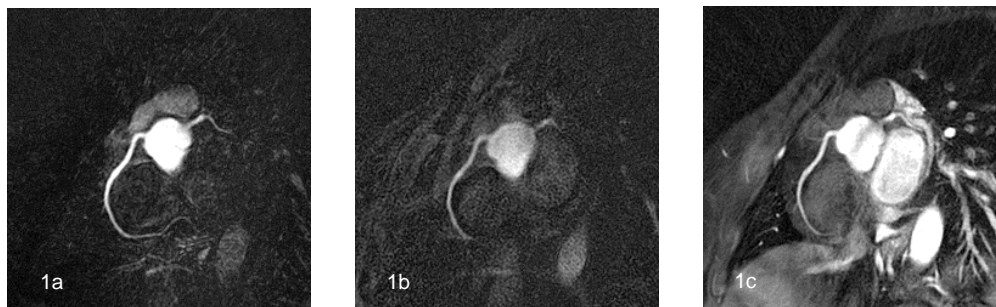


Fig. 1 a, b, c:
MRA of the RCA using *ProjSSFP* (1a),
LoReInSSFP (1b), and *InflowSSFP* (1c).

Conclusion

In this study, three coronary MRA approaches with different magnetization preparation schemes are presented providing additional blood flow information without the need of contrast agent administration. *InflowSSFP* provided highest SNR, CNR and vessel sharpness and may prove useful as a fast and efficient approach for assessing coronary blood flow, while requiring less planning skills than *ProjSSFP* or *LoReInSSFP* MRA.

References

1. Stuber M, Bornert P, Spuentrup E, Botnar RM, Manning WJ. Selective three-dimensional visualization of the coronary arterial lumen using arterial spin tagging. *Magn Reson Med.* 2002;47:322-9.
2. Stuber M, Katoh M, Spuentrup E. T1 Contrast Generation in Coronary MRA without the use of Contrast Agents. In: *Proc. Intl. Soc. Mag. Reson. Med.*; 2004.