

MR Imaging and MR Spectroscopy of Female Intra-pelvic Tumors: Preliminary Experience at 3.0 Tesla

M. Takeuchi¹, K. Matsuzaki¹, M. Harada², H. Kubo², H. Nishitani¹

¹Radiology, University of Tokushima, Tokushima, Tokushima, Japan, ²Radiologic Technology, University of Tokushima, Tokushima, Tokushima, Japan

Synopsis: Single-voxel proton MR Spectroscopy (MRS), multi-voxel proton 2D CSI, and MRI with body coil at 3.0 Tesla (T) of female intra-pelvic tumors were evaluated comparing with MRI performed at 1.5 T, with pathologic correlation.

Introduction: However the recent development of clinical whole-body MR systems at 3.0 Tesla (T) may improve signal-to-noise ratio (SNR) and spectral resolution, there is still no report of female intra-pelvic tumors evaluated by in-vivo proton MRS and MRI at 3.0 T. Actually, there are quite a few reports of gynecologic diseases evaluated by in-vivo proton MRS at 1.5T (1). The high lactate signals of the cystic lesions in the female pelvis suggest their malignant nature, and the high choline signals may reflect metabolic activity of the cell membrane of the solid gynecologic tumors (1). In this study we evaluated female intra-pelvic tumors by in-vivo proton MRS at 3.0 T, and by MRI both at 1.5 T and 3.0 T with pathologic correlation.

Materials and Methods: Six surgically proven female intra-pelvic tumors including one malignant ovarian tumor (malignant germ cell tumor), three benign ovarian tumors (two mucinous cystadenomas and one struma ovarii), one borderline malignant ovarian tumor (mucinous cystadenoma) and one benign uterine tumor (leiomyoma) were evaluated. After the measurement of MRI on a 1.5T Signa Horizon whole body scanner (General Electric, WI) with a receive-only phased-array coil, in vivo proton MRS and MRI was performed on a 3T Signa VH/i whole body scanner (General Electric, WI) with a body coil as an RF transmitter and a signal receiver. Spin echo T1-weighted images and fast spin echo T2-weighted images were obtained both on 1.5 T and 3.0 T MRI. Single-voxel proton MRS by the point resolved spectroscopy (PRESS) technique with a long TE (144ms) and the stimulate echo acquisition mode (STEAM) technique with a short TE (15ms). Multi-voxel proton 2D PRESS-CSI (TR=2000ms/TE=35ms) was also performed. The section for the CSI was selected based on axial MR images at the maximum diameter of the tumors. The metabolite ratio map was calculated and projected over the corresponding T2-weighted images.

Results and Discussion: 3T MR images showed high signal intensity for images obtained by a body coil. In two benign cystic ovarian tumors (mucinous cystadenomas), no significant peaks of metabolites were detected. In one borderline ovarian cystic tumor (mucinous cystadenoma), low lactate signal was detected suggesting its low grade malignant potential. In this tumor, Small amount of hemorrhagic components in some loculi showed more hyperintensity on T1-weighted images at 3.0 T than at 1.5 T (Fig. 1). In one benign solid and cystic tumor (struma ovarii), low signal peaks (lactate or amino acid, choline, creatine, glutamate, acetate or NAA) were detected reflecting small amount of cellular components (Fig. 2). In one malignant ovarian tumor (malignant germ cell tumor), high peak of choline was detected suggesting its high metabolic activity. The metabolite ratio map by CSI revealed high choline concentration in the tumor (Fig. 3). In one benign uterine tumor (leiomyoma with marked edematous change), choline peak was low reflecting its hypocellularity. Although this tumor showed hyperintensity on T2-weighted image resembling cellular leiomyoma or uterine sarcomas, the MRS results suggested its benign nature and might be useful for the differential diagnosis (Fig. 4).

Conclusion: MRI and MRS at 3.0 T may have advantage in diagnosis of female intra-pelvic tumors by its high signal intensity, high spectral resolution, and high susceptibility sensitivity. The metabolite ratio map may reveal the distribution of benign and malignant components in a large tumor.

Reference: 1) Okada T, Harada M, Matsuzaki K, et al. Evaluation of Female Intrapelvic Tumors by Clinical Proton MR Spectroscopy. JMRI 2001;13:912-917

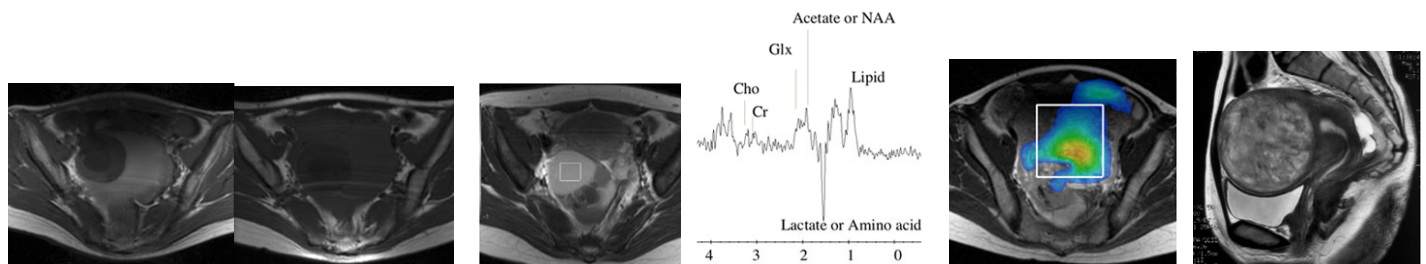


Fig. 1a: T1-WI (3.0T) Fig. 1b: T1-WI (1.5T) Fig. 2a: T1-WI (3.0T) Fig. 2b: MRS (PRESS) Fig. 3: CSI (choline map) Fig. 4: T2-WI