

3 Tesla High Resolution 3D MR Spectroscopic Imaging of the Prostate with a MLEV-PRESS Sequence

A. P. Chen^{1,2}, C. H. Cunningham³, D. Xu^{1,2}, R. E. Hurd⁴, F. V. Coakley¹, J. Pauly³, J. Kurhanewicz^{1,2}, D. B. Vigneron^{1,2}

¹Dept. of Radiology, UCSF, San Francisco, CA, United States, ²Bioengineering Graduate Group, UCSF/UCB, San Francisco, CA, United States, ³Electrical Engineering, Stanford University, Stanford, CA, United States, ⁴ASL WEST, GE Healthcare Technologies, Menlo Park, CA, United States

Introduction:

With the recent availability of 3Tesla whole body systems, the potential for improvements in spectral signal-to-noise and resolution for prostate MRSI have been explored (1-4). Currently at 1.5T, the MRSI voxels have the volume typically around 0.3 cc. To avoid partial voluming and to better characterize disease of smaller volume, higher spatial resolution at 3T is clearly desirable. The higher spectral resolution at 3T also offers better separation of choline, polyamine and creatine resonances that overlap considerably at 1.5T. However, one of the challenges for prostate MRSI at 3T is the quantification of citrate resonance. At 1.5T, citrate is strongly coupled, and an upright singlet peak is observed with PRESS localization at TE = 120-130ms (5). At 3T, however, the citrate resonance, due to J-modulation changes, is not completely upright until a echo time of 260 ms which would result in substantial T2 signal loss. To address this problem, we developed a modified PRESS sequence incorporating a nonselective rf pulse train which has the effect of refocusing the J-modulation of citrate, allowing for the acquisition of an upright citrate resonance with most of the magnetization localized to the center lines at a reasonably short TE of 85ms. The new sequence was applied in thirteen 3T MRI/MRSI prostate cancer exams to obtain high spatial and spectral resolution 3D-MRSI data.

Methods:

The modified PRESS sequence incorporates phase-modulated frequency selective spectral-spatial refocusing pulses in place of conventional refocusing pulses. These 14ms dual-band 180° refocusing pulses were designed for attenuated water refocusing and suppression of lipid (4). Between the dual-band refocusing pulses, a train of non-selective pulses utilizing the MLEV phase cycling scheme was added to refocus the J-modulation of citrate (Fig.1). At echo time of 85ms, with eight or twelve 800 μs hard pulses placed between the selective refocusing pulses in the refocusing train, a completely upright citrate resonance with minimal outer lines was observed. The new sequence was applied in thirteen prostate patient exams on a GE 3T MR scanner using body coil excitation and 3T MEDRAD prototype endorectal coils or a custom designed rigid endorectal coil in conjunction with a pelvic phased array coil for signal reception. The 3D MRSI data were acquired in 17 minutes with a spatial resolution of 0.15cc (compared to 0.3cc at 1.5T) and a spectral resolution of 2000Hz/1024pts. Seven of the patients were also studied at 1.5T using standard acquisition protocol.

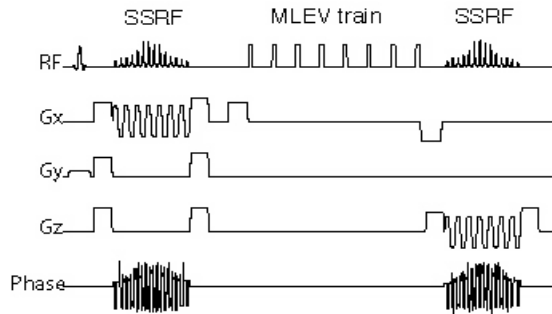


Figure 1. The MLEV-PRESS sequence for prostate MRSI at 3T. Conventional refocusing pulses are replaced with phase-modulated spectral-spatial pulses (SSRF). The non-selective refocusing pulse train is added between the SSRF and employed a MLEV phase-cycling scheme for B1 insensitivity.

Results:

High quality 3D MRSI data were obtained in the patient studies at 3T, with a completely positive absorptive pattern for citrate resonances (Fig. 2). For the seven patients studied at both 3T and 1.5T, the 3T SNR for citrate peak heights was 1.8-fold higher than for the corresponding 1.5T data. High levels of citrate were observed in healthy peripheral zones and in the regions of prostate cancer elevated choline and reduced citrate were observed (Fig. 2-3). The higher spatial resolution at 3T provided noticeably better metabolic characterization of individual tumors than 1.5T (Fig. 3). Robust lipid suppression was achieved in all 3T MRSI studies.

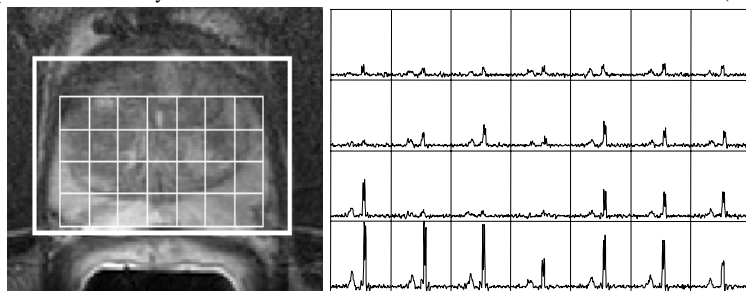


Figure 2. Prostate MRSI at 3T using the modified PRESS sequence. 68 year-old patient with no biopsy and no evidence of prostate cancer in three prior studies. High level of citrate is observed in the peripheral zone with completely upright peak and the sidebands reduced to near baseline.

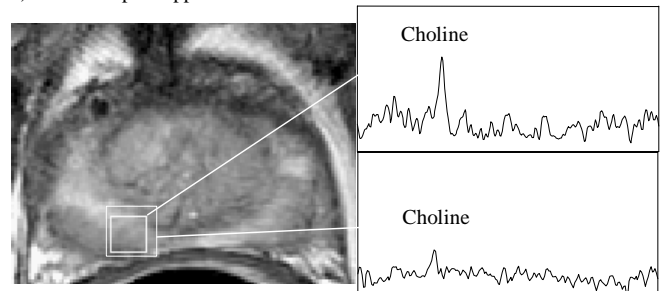


Figure 3. Sixty-eight year old prostate patient with biopsy confirm prostate cancer (G4+5) scanned at both 3T (top, 0.15cc) and 1.5T (bottom, 0.3 cc) two years after hormone therapy. Note the higher spatial resolution at 3T provided better metabolic characterization of the residual/recurrent cancer.

Discussion:

In this study, a 1.8 fold increase in SNR was observed for prostate MRSI acquired at 3T as compared to 1.5T. The MLEV- PRESS sequence developed for 3T prostate MRSI was shown to provide an upright citrate peak that allowed fast and robust quantification of citrate at echo time of 85ms. The phase-modulated dual-band spectral spatial refocusing pulses also provided robust lipid suppression. By acquiring 3D prostate MRSI data at a higher spatial resolution at 3T, sensitivity of prostate MRSI for small volume disease may be increased. The higher spectral resolution at 3T and the completely upright citrate peak with reduced side band may also allow more accurate quantification of choline, polyamine, creatine and citrate peaks, thereby improving the detection of abnormal metabolism in regions of prostate cancer.

References:

1. Futterer JJ, et al. Invest. Radiol. 2004 Nov; 39 (11): 671-680.
2. Vigneron DB, et al. ISMRM abstracts, 2004: #386.
3. Scheenen T, et al. ISMRM abstracts, 2004: #385.
4. Cunningham CH, et al. ISMRM abstracts, 2004: #682.
5. Heerschap A, Magn Reson Med, 1997 Feb; 37 (2): 204-13.

Acknowledgment: NIH RO1-CA59897