

Ex vivo MR imaging of atherosclerotic rabbit aorta labelled with USPIO – Enhancement of iron loaded regions in UTE imaging.

L. A. Crowe¹, Y-X. Wang², P. Gatehouse¹, J. Tessier², J. Waterton², P. Robert³, G. Bydder⁴, D. N. Firmin¹

¹Cardiovascular Magnetic Resonance Unit, Imperial College / Royal Brompton Hospital, London, United Kingdom, ²Imaging Centre, AstraZeneca Pharmaceuticals, Macclesfield, United Kingdom, ³Experimental Imaging, Geurbet Group, Roissy, France, ⁴Radiology, University of California, San Diego, California, United States

Aim: To assess enhancement of USPIO labelled regions of atherosclerosis with ultra-short TE (UTE) imaging compared to USPIO detection by GRE signal loss. The overall objective is to provide a means to quantify macrophages infiltration in atherosclerotic plaques and develop a biomarker for plaque inflammation.

Introduction

USPIO is known to accumulate in atherosclerotic lesions, particularly in macrophages and regions of inflammation, and will affect images via T2* relaxation properties.¹⁻⁵ The effect on T1 weighted sequences shows an enhancement at low dose followed by signal loss.⁶ Here, we describe a novel application of UTE sequence^{7,8} to image the regions of USPIO (Sinerem; Guerbet, France) uptake in atherosclerotic rabbit aorta. Methods previously reported rely on signal loss in regions high in iron, but this can often be confused with signal from calcification in atheromatous plaque in diseased vessels. Paramagnetic effects in the region of the signal loss may also lead to distortion of the vessel shape. The short T2 properties of the iron labelled regions show up as high intensity in a UTE subtraction image. We aim to use UTE and USPIO to quantify the inflammation in plaques. This is very challenging with GRE as USPIO induces signal loss.

Methods

Specimen Preparation: Eight 77 weeks old WHHL rabbits were given USPIO in varying doses (0, 125, 250 and 500µmol/kg). After 3 days, the rabbits were heparinised and deeply anaesthetised. The cardiovascular system was flushed with phosphate buffered saline and then 4% formalin at a pressure of 80mmHg through a needle put in to the left ventricle. After perfusion fixation, the heart and aorta were dissected out and kept in 4% formalin. The thoracic aorta showed extensive atherosclerosis.

MR Scanning: All scans were carried out on a Siemens Magnetom Sonata 1.5T Scanner. The thoracic aorta specimens were scanned in two batches with one of each different labelling concentration and a control (batch 1: A.125, B. 500, C. 0, D. 250 µmol/kg, batch 2: E.0, F. 250, G. 125, H. 500 µmol/kg). A home built PTFE sample/coil holder was used with small loop coil touching base of sealed box containing samples. All this was enclosed in a larger Perspex box connected to an air heater via insulated tubing for heating to and maintaining the samples at body temperature during scanning. Scans were orientated from multislice trueFISP pilots and a 3D T1-weighted TSE for morphology. This ensured the vessels were perpendicular to the UTE imaging slices. All images were repeated with and without fat saturation to help identify the structure of the aorta wall.

Two UTE protocols were used; one with the maximum resolution and 4µs sampling, and one with lower resolution, but a faster sampling. Two images are acquired with ultra short and 'long' TE and a subtraction image is calculated.

UTE High Resolution: TR 300ms, TE[1] 0.08ms, TE[2] 4.83ms, 6 slices, 5mm thickness, 5mm gap, FOV 125x125mm, matrix size 512*512, 6 averages.

UTE Fast sampling: as above, but with TE[2] 2.79ms, FOV 250 x 250mm.

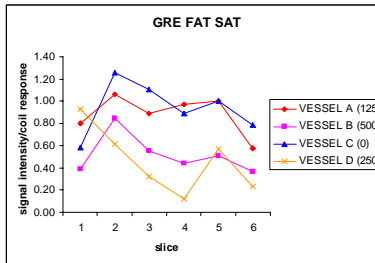
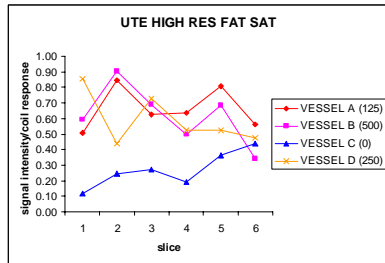
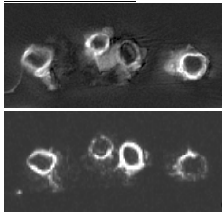
3D GRE images were acquired to compare areas of signal loss with UTE enhancement (TR 90ms, TE 10ms, 32 x 2mm slices, FOV 100x50mm, matrix size 256*256).

Concentration Effects: The effect on signal intensity of USPIO in saline solution at concentrations from 0.005 to 5mM was observed with the same imaging parameters.

Analysis of MR Images: Analysis of images and quantification of signal in regions of interest was carried out using CMRTTools software. The small coil used to maximize SNR has a small area of maximum coil response, and consequently the order of the vessels in the two sets was altered so as not to bias results. In addition, a corresponding area on the uniform phantom images was used to normalise for coil response. Mean wall signal intensity for each vessel and slice was measured.

Results and Discussion

Ex-vivo Results



Statistically significant difference (mean of all labelled vessels, compared with mean of control vessels by paired t-test) was seen for signal intensity in both UTE enhancement and GRE signal loss.

UTE – mean labelled 0.67, control 0.41, p = 0.001.

GRE – mean labelled 0.68, control 0.98, p = 0.0003.

There was variation in signal intensity observed between slices and around the vessel circumference. Overall SNR was low in the outermost slices, making comparison more difficult. Uptake of USPIO was quantified via signal intensity as shown in the figures for each slice through the vessel wall. Depending on plaque composition, uptake may not be homogenous, even though at the age of 77 weeks old, atherosclerotic lesions are diffused in these rabbits.

For all three different injection doses, the enhancement due to USPIO uptake concentration is similar.

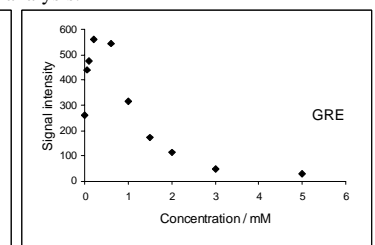
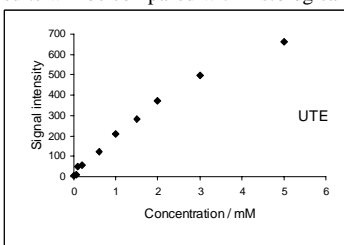

In previous studies, calcifications were found to be a major source of false positive MR diagnosis in standard imaging for USPIO signal loss as they also appear black². This should not be the case when looking at short T2 species enhancement. These results will be compared with histological analysis.

Phantom Results.

There is a linear correlation between signal intensity and concentration in UTE whereas with GRE, the signal intensity relationship is complex with an initial increase from T1 effects and T2* causing signal decrease at concentrations >0.2mM. In the UTE scan, for the control and concentration 0.05mM there is no signal present on the subtraction image showing all short T2 subtraction signal in this phantom is from the USPIO.

concentration / mM

3	0.1	1.5	0	0.05
0.2	1	2	5	0.6



Conclusions

UTE images of the uptake of intravenous USPIO (Sinerem) in atherosclerotic rabbit aorta are reported. The enhancement due to the presence of short T2 USPIO accumulation generally agrees with signal loss in GRE. Three doses of USPIO were studied along with a control. The effect on UTE and GRE signal was quantified in USPIO solutions of varying concentrations for validation of the effects seen in the vessel wall. UTE enhancement shows a linear relationship to USPIO concentration. This provides the possibility to develop quantification of macrophages infiltration in atherosclerotic plaques.

¹ Ruehm SG, Corot C, Vogt P, et al. Circulation. 2001;103:415-22.

² Schmitz SA, Taupitz M, Wagner S, et al. Invest Radiol. 2002;37:405-11.

³ Kooi ME, Cappendijk VC, Cleutjens KB, et al. Circulation. 2003;107:2453-8.

⁴ Trivedi RA, U-King-Im JM, Graves MJ, et al. Stroke. 2004;35:1631-5.

⁵ Corot C, Petry KG, Trivedi R, et al. Invest Radiol. 2004;39:619-25.

⁶ Chambon C, Clement O, Le Blanche A, et al. Magn Reson Imaging. 1993;11:509-19.

⁷ Gold GE, Pauly JM, Macovski A, et al. Magn Reson Med. 1995;34:647-54.

⁸ Gatehouse PD, Bydder GM. Clin Radiol. 2003;58:1-19.