

Characterization of atherosclerotic plaque of carotid arteries with histopathological correlation: Vascular wall MR imaging vs Doppler US

Y. Watanabe¹, M. Nagayama¹, K. Yoshida², S. Yamagata², A. Okumura¹, Y. Amoh¹, T. Suga¹, T. Tabuchi¹, M. Obara³, M. V. Cauteren³, H. Mitsui¹, K. Nakada¹, N. Morimoto¹, M. Kumashiro¹, S. Komaki¹, T. Kiyono¹, Y. Dodo¹

¹Dept. of Radiology, Kurashiki Central Hospital, Kurashiki, Okayama, Japan, ²Dept. of Neurosurgery, Kurashiki Central Hospital, Kurashiki, Okayama, Japan, ³Philips Medical Systems Corporation, Minato-ku, Tokyo, Japan

Purpose: To investigate whether vessel wall MR imaging would yield more accurate characterization of carotid plaque with histopathological correlation than Doppler US.

Introduction: The most common source of emboli in transient ischemic attacks and embolic stroke arise from atherosclerotic disease of the carotid bifurcation. The severity of atherosclerosis may be determined by assessing both luminal stenosis and plaque morphology. Assessment of luminal stenosis alone is limited in predicting the clinical outcome and the natural history of the disease. Characterization of plaque components such as lipid core, intraplaque hemorrhage, fibrous plaque, calcification, etc is essential to evaluate atherosclerotic plaque vulnerability. Both vessel wall MR imaging and Doppler US are non-invasive imaging technique capable of assessing atherosclerotic plaque vulnerability. The purpose of this study was to investigate whether vessel wall MR imaging would yield more accurate characterization of carotid plaque than Doppler US.

Materials and methods

Patients

This study included 18 carotid arteries in 18 patients who underwent carotid endarterectomy. Intraoperative findings and microscopic examination of endarterectomy specimens revealed stable fibrous plaque in 10 patients and risky soft plaque in 8 patients.

MR Imaging

MR imaging was performed with 1.5 T units (ACS-NT, Intera; Philips). All the images were obtained with a circular surface coil with 8-cm diameter. MR angiography was performed with 3D TOF sequence. Then, vascular wall MR imaging was performed using black-blood TSE sequence with double inversion recovery technique and ECG-triggering. Fat signal was suppressed by chemical shift-selective fat suppression technique. Three contiguous sections of Transaxial fat-suppressed T1- and T2-weighted TSE images of carotid arteries were obtained.

Doppler US was performed using Logiq 500 (GE) with a 6.5 Mhz linear probe.

Assessment of plaque

Signal intensity index (SII) of carotid plaque was measured by signal intensity of plaque divided by signal intensity of submandibular or parotid gland. The MR criteria used for diagnosis of plaque vulnerability was: risky soft plaque including lipid core and/or intraplaque hemorrhage when SII is 1.25 or higher in either FS-T1 or FS-T2 images, stable fibrous plaque when SII is less than 1.25 in both FS-T1 and FS-T2 images. The US diagnosis was performed according to the criteria of Geroulacos et.al (1993). The MR and US findings were compared with histopathological findings of endarterectomy specimens.

Results

1. Among 18 patients, carotid artery was difficult to assess by vessel wall MR imaging in one patient due to motion artifact and by Doppler US in 2 patients due to high carotid bifurcation and severe calcification.
2. MR imaging correlated well with histopathological findings in 17 (94%) of 18 patients.
3. Doppler US showed 50 % (9/18) agreement with histopathological findings.

Conclusion

Vessel wall MR imaging gives excellent image contrast of carotid plaque, which will allow for more accurate evaluation of atherosclerotic plaque vulnerability than Doppler US.

FIGURE 1

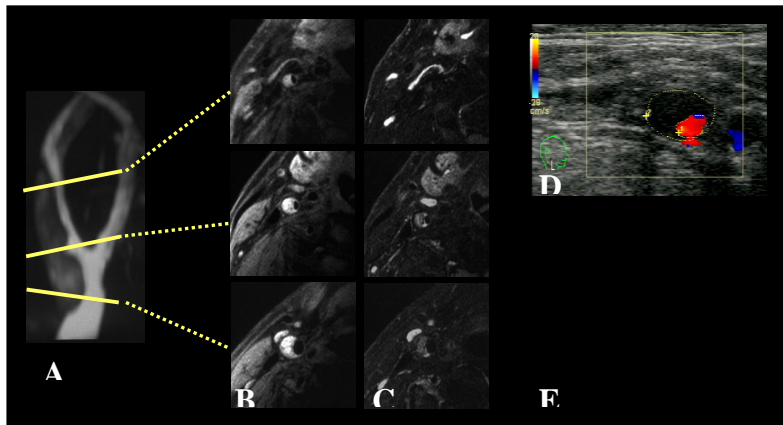


Fig.1 Risky soft plaque: MR and US findings agreed with histopathological findings

- A. 3D TOF MR angiography of carotid artery,
B. FS-T1, C. FS-T2, D. Doppler US,
E. intraoperative findings of soft plaque.

FIGURE 2

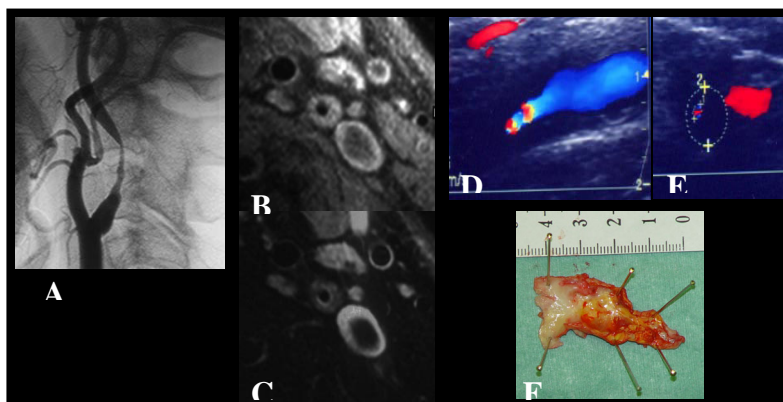


Fig.2 Stable hard plaque: MR correlated well and Doppler US disagreed with histopathological findings.

- A. DSA, B. FS-T1, C. FS-T2, D-E. Doppler US,
F. excised hard fibrous plaque