

## Functional MRI of the spinal cord at low field

K. K. Wong<sup>1</sup>, M. C. Ng<sup>1,2</sup>, Y. Hu<sup>2</sup>, D. K. Luk<sup>2</sup>, Q. Y. Ma<sup>1</sup>, E. S. Yang<sup>1</sup>

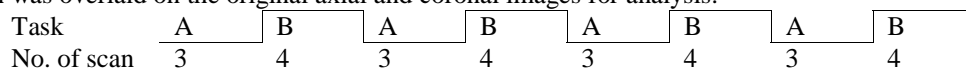
<sup>1</sup>Jockey Club MRI Engineering Centre, University of Hong Kong, Hong Kong, <sup>2</sup>Department of Orthopaedic Surgery, University of Hong Kong, Hong Kong

### Introduction

In these few years, fMRI has been shown to be feasible in the spinal cord in both 1.5T and 3T. It was found that the activation areas correlated well with the knowledge of the neural anatomy (1-6). On the other hand, it has been suggested that the activation observed with spin-echo fMRI is partly due to BOLD and partly due to signal enhancement due to extravascular water protons (SEEP) in the spinal cord (7). Since the change in extravascular proton density is field independent, and the BOLD effect would be diminished to a negligible level with short echo time and low magnetic field, it was shown that low field functional MRI based on SEEP effect was possible in the brain (8). However, the SEEP effect has not been investigated in the spinal cord at low field. Therefore, in this study, we try to detect the presence of SEEP in the spinal cord by motor task at 0.2T.

### Methods

fMRI studies were carried out on a volunteer with a 0.2T MRI scanner developed in-house. A neck coil was developed to enclose C6 to C8 nerve levels. Spin-echo pulse sequence was used. Motor stimulation was achieved by squeezing two tennis balls with both hands. The exercise paradigm used was a block design of alternative rest and motor tasks with different number of scans (3 rest, 4 stimulations), total up to 28 scans (figure 1). Proton density weighted-imaging was used. The pulse sequence parameters were: TR=1000ms, TE=14ms, FOV=140mm, slice thickness=6mm, no. of slice=7, matrix size=64\*128, and NEX=2. The data obtained was processed and analyzed by using SPM99 (9). This software realigned the raw images of the spinal cord to get rid of most of the motion artifacts during the fMRI studies. The spinal cord was then segmented by an image mask. A statistical map was generated ( $P < 0.05$ ) which was overlaid on the original axial and coronal images for analysis.



**Fig 1:** exercise paradigm where A stands for rest and B stands for squeezing balls

### Results

The activation map is shown in figure 2. It was observed that activation could be detected at the anterior grey horns of the spinal cord bilaterally across several contiguous slices (fig 2). Apart from that, some discrete activation points could also be found at the posterior grey horns on some slices (not shown in the figures).

### Discussion and Conclusions

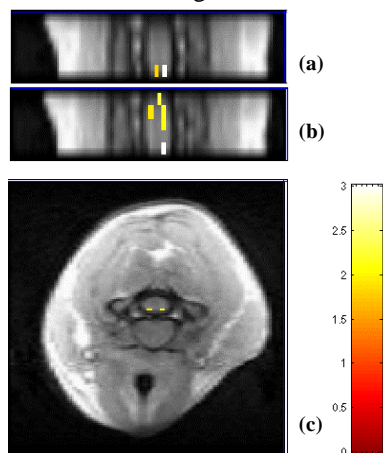
The anterior corticospinal tract controls motion especially of the hands. The cell bodies of the association neurons and lower motor neurons inside the tract are all located at the anterior grey horns of the spinal cord. When the subject tried to squeeze the balls, it provided stimulation to the motor areas at around C6-T1 levels. Therefore, activations were found at the anterior part. On the other hand, the sensation signal of the hands travels along the anterior spinothalamic tract and the neurons synapse at around C6-8 levels. As the cell bodies of the primary, association and secondary neurons inside the tract are all at the posterior grey horns, some activations were also found at the posterior part. There were more activations in the motor areas than in the sensory areas because the subject was holding the balls during rest and during motor task. These two states would give sensory stimulation to the spinal cord. Therefore, it makes the sensory stimulation less correlated with the paradigm. All these results suggested that the activation obtained correlated well with the knowledge of neural anatomy and this verified that the SEEP concept is present in the spinal cord at low field.

### Acknowledgement

We would like to thank Mr. Francis KH Lee for his help on the design of the neck coil and thank Dr. KM Hong for his generous support. We would also like to acknowledge Jockey Club Charity Trust for the funding support.

### References

1. Yoshizawa T et al., Neuroimage. 1996 Dec; 4(3 Pt 1):174-82.
2. Stroman P.W. et al., Magn Reson Med 1999 Sep;42(3):571-6
3. Stroman P.W. et al., Magn Reson Imaging 2001 Jan;19(1):27-32
4. Stroman P.W. et al., Magn Reson Imaging. 2001 Jul;19(6):833-8.
5. Stroman P.W. et al., Neuroimage. 2002 Dec;17(4):1854-60.
6. Stroman P.W. et al., Magn Reson Imaging. 2002 Jan;20(1):1-6.
7. Stroman P.W. et al., Magn Reson Med. 2002 Jul;48(1):122-7.
8. Stroman P.W. et al., Neuroimage. 2003 Oct;20(2):1210-4.
9. Wellcome Department of Imaging Neuroscience, Statistical Parametric Mapping.



**Figure 2:** activation map in the cervical spinal cord on (a) anterior coronal plane, (b) anterior coronal plane 1.1mm adjacent to a, (c) axial plane. The color bar shows the t value