

Basal Ganglia Neurodegeneration in Multiple Sclerosis Measured by Dynamic Susceptibility Contrast MRI

Y. Ge¹, M. Law¹, G. Johnson¹, L. J. Mannon¹, J. Herbert², R. I. Grossman¹

¹Radiology, New York University Medical Center, New York City, NY, United States, ²Neurology, Hospital for Joint Diseases, New York City, NY, United States

INTRODUCTION: Microvascular occlusion due to fibrin deposition and hyalinised collagen in the vein wall has long been noted in multiple sclerosis (MS) [1]. Recent studies based on advanced histopathological techniques have further confirmed that there is hypoxia-like metabolic tissue injury in MS lesions [2,3]. Thus, the attention has been directed toward whether there is hemodynamic impairment in MS that could be a component of pathology and whether the cerebral perfusion abnormality could be an indicator of disease extent, severity and progression in this chronic inflammatory demyelinating disease. In this study, we studied the microcirculation in the basal ganglionic gray matter in patients with relapsing remitting (RR) MS using dynamic susceptibility contrast MR imaging (DSC-MRI), knowing that gray matter is also affected by the disease with significant neuronal loss and neurodegeneration [4,5].

MATERIALS AND METHODS: Seventeen patients with clinical relapsing remitting MS were recruited for this study. Imaging was performed on a 1.5T Siemens Vision imager (Siemens Medical Systems, Iselin, New Jersey). 12 controls were also selected for comparison. After conventional MR imaging, which included T2- and T1-weighted images, a series of 60 gradient-echo echo-planar images were acquired at 1-second intervals during the first pass of a standard dose (0.1mmol/kg) bolus of gadopentetate dimeglumine. Seven 3 mm thick slices of DSC-MRI were acquired and positioned parallel to the AC-PC plane, ensuring that at least one slice included the basal ganglia. Absolute perfusion parameters for cerebral blood volume (CBV), cerebral blood flow (CBF), and mean transit time (MTT) were computed using an automated method for calculation of artery input function (AIF) [6,7]. Measurements were made in 2 subregions of putamen and thalamus in each hemisphere in patients and controls. The mean values for each perfusion parameter in each region were obtained for the analysis.

RESULTS: DSC-MRI perfusion parameters of CBV, CBF, and MTT expressed as mean and standard deviation (SD) for putamen and thalamic gray matter in patient and control groups are summarized and compared in Table 1. All perfusion parameters in both putamen and thalamus showed significant differences ($p \leq 0.01$) between patient and control groups, indicating there is a significant hypoperfusion in patients with MS as shown in Figure 1.

Table 1. Measured perfusion parameters in thalamus and putamen for patients versus controls

| Subjects | Thalamus | | | Putamen | | |
|----------|-------------|-------------|-------------|-------------|-------------|-------------|
| | CBF | CBV | MTT | CBF | CBV | MTT |
| MS | 25.6 ± 11.7 | 1.98 ± 0.57 | 3.38 ± 0.81 | 36.1 ± 17.0 | 1.86 ± 0.65 | 3.20 ± 0.83 |
| Control | 65.9 ± 14.8 | 3.80 ± 1.01 | 2.90 ± 0.55 | 87.9 ± 15.4 | 4.24 ± 0.74 | 2.68 ± 0.45 |
| P Values | < 0.0001 | < 0.0001 | 0.01 | < 0.0001 | < 0.0001 | 0.004 |

Note: CBF: (ml/100g tissue/min); CBV: (ml/100g tissue); MTT: (seconds)

CONCLUSION: These results suggest that there is significant decreased blood perfusion in basal ganglionic gray matter in patients with MS and that measurements of cerebral blood perfusion using DSC-MRI may be

useful as an indicator of brain neurodegeneration in MS. Because cerebral blood flow is critical in maintaining the brain function and metabolism, the basal ganglia hypoperfusion in MS may have clinical relevance for understanding cognitive dysfunction. However, further study will determine if hemodynamic impairment in the deep gray matter is a primary (ie. ischemic pathogenesis from vascular inflammation /lymphocytic infiltration) or secondary event (ie, reduced metabolic demand due to widespread parenchymal injury / reactive astrogliosis) in the disease.

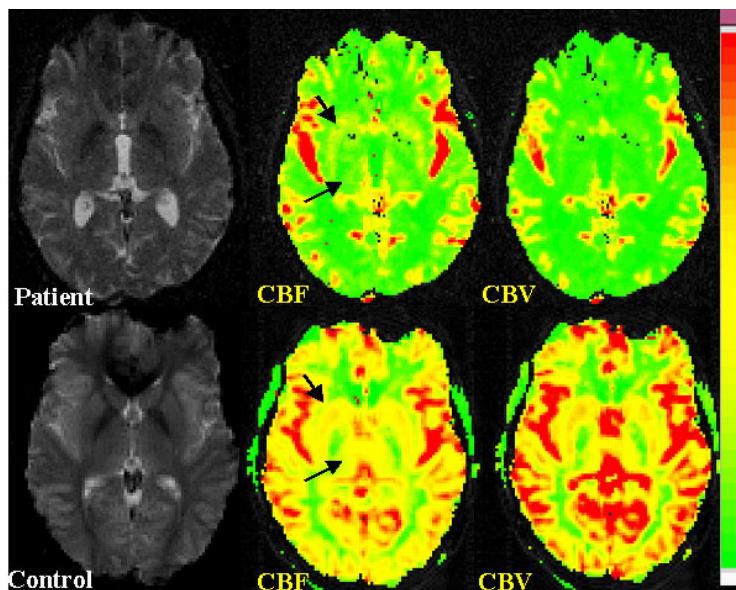


Fig 1. Color maps of CBF and CBV in a control (bottom) and a patient (top) at the level of basal ganglia. The perfusion is significantly decreased in thalamic and putamen gray matter (arrows) in the MS patient compared with the control subject.

REFERENCES:

1. Putnam TJ. Arch Neurol Neuropsychol 1935; 1298-1321
2. Wakefield A. et al. J Clin Pathol 1994;47:129-133
3. Lassmann H. J NeurolSci 2003;187-191
4. Peterson JM. et al. Ann Neurol 2001;50:389-400
5. Cifelli A et al. Ann Neurol 2002;52:650-653
6. Carroll TJ. et al. Radiology 2003;593-600
7. Rempp KA. et al. Radiology 1994;193:637-641

ACKNOWLEDGEMENTS:

This work was supported by grants R37 NS29029-11 from NIH and NCRR M01 RR00096 (GCRC)