

Prostate MRI and MRS at 3T: Using Phased Surface Coil Array

H. Mao¹, X. Hu^{2,3}, K. Heberlein², R. Smith², W. Torres¹

¹Department of Radiology, Emory University School of Medicine, Atlanta, Georgia, United States, ²Department of Biomedical Engineering, Emory University School of Medicine, Atlanta, Georgia, United States, ³Georgia Institute of Technology, Atlanta, Georgia, United States

INTRODUCTION

Prostate cancer is the most common cancer and the second most frequent cause of cancer death in men in the United States. Early detection, staging and treatment monitoring are important for defining the treatment strategy and reducing mortality rate. Imaging modality that can improve clinical management of prostate cancer is desirable. One promising technique is to use the combination of magnetic resonance imaging (MRI) and magnetic resonance spectroscopy (MRS) which not only can imaging with high spatial resolution and tissue contrast but also measuring the content of relevant metabolites in the prostate¹. However, conventional prostate MRI is done at 1.5 Tesla, using endorectal probe. Our approach to improve current prostate MRI and MRS is to use specially designed receiving-only phased surface coil array for prostate MRI and MRS at 3T.

METHODS

This study was conducted on a Siemens 3T trio whole body scanner. Five health volunteers and three patients with benign prostatic hyperplasia (BPH) were studied using either a commercial phased coil array or a receiving-only phased surface coil array developed in our lab, which has 4 coil elements paired in two separated units. Three of the subjects also received phase array imaging at a 1.5T scanner (Philips 1.5T Intera).

The subject is positioned in the scanner feet-first in supine position with the phased array surface coil set wrapped around the pelvis. All 4 elements of the coil array were used for data collection. Typical prostate imaging includes a T2-weighted scout, a T1 weighted axial, T2 weighted axial, sagittal and coronal scans. FOV of 180 mm and 9 or 12 slices with slice thickness of 4 mm were used, covering the prostate. Acquisition parameters include: TR/TE=3900/110 ms and imaging matrix of 256², reconstructed to 512², using a fast spin echo sequence. The total exam takes about 40 to 50 minutes. For MRS, single voxel technique was used with voxel size of 12 mm³, positioned in the central zone and transition zone of the prostate gland. MR spectra were collected using TR of 2000 ms, TE of 128 ms, sweep width of 2000 Hz, 512 data point, and 312 transients with phase cycling, a total of 8 minutes of data collection time. Localized shimming was used. Water suppression was accomplished using chemical shift selective suppression (CHESS) method, while no fat suppression was applied. Collected time domain FIDs were Fourier-transformed after data were zero filled to 2K and with Gaussian filter for line-broadening. Chemical shifts of the metabolite were calibrated using water as the internal standard at 4.65 ppm. In both MRI and MRS, data were collected by all coil elements simultaneously and combined during the procession.

RESULTS

Prostate images can be obtained without using the endorectal probe. **Figure 1 (a)** demonstrated an axial T2-weighted image obtained from a patient with mild BPH. Prostate imaging at 3T provides significant improvement in spatial resolution. Using localized shimming, local field inhomogeneity, a problem magnified at 3T, can be minimized for prostate imaging. In addition, the 3T prostate image has improved image contrast for defining the zonal structure of the prostate. The capsular structure of the prostate and peripheral zone were better visualized with "brighter" signal in T2 weighted imaging compared to phased array images obtained at 1.5T. This feature could be potentially beneficial for better localizing and identifying lesions developed at the peripheral zone, because they are commonly found with reduced signal in T2 weighted imaging. Improved definition of the capsule and the peripheral zone should also allow for better visualization of certain pathology such as irregular bulging of the prostate, focal thickening, extracapsular extension (ECE), and seminal vesicle invasion (SVI). Therefore, diagnostic value of prostate imaging can be improved. Another remarkable feature of the phased array imaging is that it provides coverage of extended area that is surrounding the prostate. Such uniformed imaging quality is not available from the conventional endorectal imaging. In our study, we were able to visualize several iliac lymph nodes with high resolution. **Figure 1 (b)** showed a prostate spectrum obtained from a patient with mild BPH using single voxel technique. Signal and quality of the spectrum was improved after combining signals collected from three coil elements individually. All metabolites of interest, choline, creatine and citrate, were well resolved at 3T.

DISCUSSIONS

Although endorectal imaging has the advantage of high sensitivity in the prostate MRI and particularly in prostate MRS, it has significant limitations, e.g., the small field of view that limits visualizing the surrounding tissues of the prostate; requiring tedious setup and causing extreme discomfort to the patient, particularly to those patients who have clinical conditions in the rectum. In many cases, insertion of the endorectal coil and inflation of attached air-balloon can lead to the deformation of the prostate anatomy, potentially introducing errors in the spatial localization. In comparison, the phased array prostate MRI does not have such limitations²⁻³. Using multi-element phased array coil and the high field (3T), prostate imaging can be performed to the satisfaction of clinical application. Furthermore, prostate MRS is feasible at 3T using the phased array surface coil. This is especially attractive for quantifying metabolites because of improved spectral resolution at the high field. In summary, phased array MRI and MRS at 3T offers improved spatial resolution and spectral resolution without significant imaging artifact. Clinical utility of 3T phased array prostate MRI and MRS for management of prostate diseases is possible.

(Supported by the Wallace Coulter Foundation)

1. Kurhanewicz J, Swanson MG, Nelson SJ, Vigneron DB: *J Magn Reson Imaging*. 2002;16(4):451-63.
2. Kaji Y, Wada A, Imaoka I, Matsuo M, et al. *J Magn Reson Imaging*. 2002;16(6):697-706.
3. Kim HW, Buckley DL, Peterson DM, Duensing GR, Caserta J, Fitzsimmons J, Blackband SJ: *Invest Radiol*. 2003;38(7):443-51.

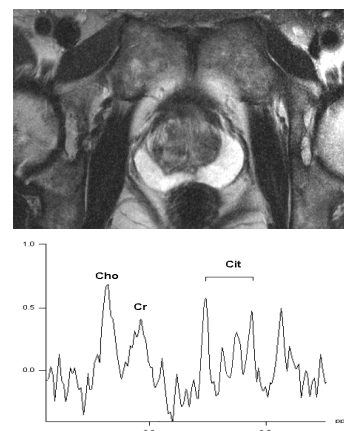


Figure 1. (a) A T2 weighted prostate image by a phased surface coil array at 3T was obtained with 0.4 mm in-plane resolution in 8 mins. (b). A single-voxel (12 mm³) prostate spectrum at 3T.