

# Therapy Monitoring of the Prostate with MRI by Assessment of the Volume and of Substructures within the Gland

H. Polzer<sup>1</sup>, H. Henry<sup>1</sup>, J. T. Heverhagen<sup>1</sup>, K. T. Baudendistel<sup>1</sup>, G. Jia<sup>1</sup>, H. von Tengg-Kobligk<sup>2</sup>, H. Chun<sup>1</sup>, T. J. Rosol<sup>3</sup>, M. V. Knopp<sup>1</sup>

<sup>1</sup>Department of Radiology, The Ohio State University, Columbus, OH, United States, <sup>2</sup>Department of Radiology, German Cancer Research Center (DKFZ), Heidelberg, Germany, <sup>3</sup>Department of Veterinary Biosciences, The Ohio State University, Columbus, OH, United States

**Introduction:** Benign prostate hyperplasia (BPH) is a common age related disease in men and beagles. 50% of men in their 60s and about 80% in their 80s suffer from BPH (1). Extensive effort is put into research to find a reasonable tool to diagnose BPH and to monitor its therapy. The purpose of this study was to monitor the prostate volume under therapy using 3D MRI. Furthermore, we wanted to observe changes in different regions and tissues of the gland.

**Subjects and Methods:** The study was approved by the local animal care committee. 12 male beagle dogs (mean age  $\pm$  standard deviation,  $4.4 \pm 0.9$  years) with spontaneous age related BPH (prostates were  $>2\text{cm}$  on digital palpation) were divided into a treatment group and a control group. The treatment group received a daily dose of  $1\text{ mg/kg}$  finasteride ( $5\text{-}\alpha$ -reductase inhibitor), the control group received placebo treatment. All dogs were imaged five times (week  $-3, 0, +4, +8, +12$ ) twice before and three times under treatment. Two days after the last MRI examination the dogs were sacrificed and the ex vivo prostate volume was measured by water displacement.

For image acquisition a 1.5T clinical scanner (Twinspeed, GE, Milwaukee, WI) with a standard head coil was used. The MR examinations included  $T_1$  (TR 500 ms, TE 20 ms, FA  $90^\circ$ , Th 2mm, BW 21.74 kHz, NEX 1, Matrix  $256 \times 256$ , FoV  $14 \times 14\text{ cm}^2$ , no gap) and  $T_2$  (TR 2000 ms, TE 105 ms, FA  $90^\circ$ , Th 2mm, BW 17.86 kHz, NEX 1, Matrix  $256 \times 256$ , FoV  $14 \times 14\text{ cm}^2$ , no gap) weighted series in the axial and coronal plane. Semi automated slice by slice segmentation was used to assess the volumes from the  $T_1$  and the  $T_2$  images in the axial plane. Thereby, the in vivo prostate volume was determined using the MIPAV software package running under windows (2). Furthermore we assessed the volume of the periurethral region by manually placing a volume of interest (VOI) around it. The volume of the whole gland minus the volume of the periurethral region was considered to be the glandular portion of the prostate.

To validate the appearance of the different prostatic regions in the MR images an additional dog was imaged. After necropsy histological slides were obtained according to the MR imaging plane, the slice location and the position of the axial cross-sections. These slides were correlated to the corresponding MR images. The manually drawn periurethral VOI was placed according to the findings in histology (Fig. 1).

To determine statistically significant differences a student's t-test was used. The correlation between volumes was calculated according to Pearson. p-values below 0.05 were considered to be statistically significant.

**Results:** The average segmented prostate volume in study 5 (immediately pre-necropsy) was  $12830\text{ mm}^3$  with a SD of  $6780\text{ mm}^3$ . MRI volumes overestimated the post necropsy water displacement measurements by 7.2% on average. However, both measurements showed a statistically significant correlation of 0.99 ( $p < 0.05$ , Pearson).

Prior to treatment, comparison between the control and the treatment group regarding the volumes of the whole prostate, the glandular tissue and the periurethral region showed no significant mean differences ( $p > 0.05$ ). Prior to treatment, the average volume of the entire gland of the control group was  $17100\text{ mm}^3$  (SD  $6200\text{ mm}^3$ ) and  $16100\text{ mm}^3$  (SD  $5100\text{ mm}^3$ ) in the finasteride group.

Comparing the volumes of all 12 dogs in study #1 to the volumes in study #2 no significant differences could be observed in any of the prostatic regions ( $p > 0.05$ ).

During treatment the control group showed no significant change in the average prostatic volume. The average volume of the studies #3, #4, and #5 were  $17200\text{ mm}^3$ ,  $16900\text{ mm}^3$ , and  $16900\text{ mm}^3$ . In contrast the average volume in the treatment group decreased to  $10500\text{ mm}^3$ ,  $9600\text{ mm}^3$ , and  $8800\text{ mm}^3$  respectively. In all the studies under treatment the differences between the control group and the treatment group were significant ( $p < 0.05$ ) in all the assessed areas (total, glandular and periurethral volume). The following relative values refer to the average volume of the corresponding regions of the same group prior to treatment. The mean prostate volume decreased continuously to 65% (study#3), 60% (study#4), and 53% (study#5). Similarly, the mean glandular tissue volume decreased to 63%, 58% and 51%. The periurethral region in contrast had an average residual volume of 78%, 72% and 63% (Fig. 2).

Histological slices could clearly be correlated by using reference points such as atrophic or cystic areas.

**Discussion:** Physiologic changes occur when removing the prostate from its natural environment. The lack of perfusion, no neural integrity and no longer being affected by surrounding tissues leads to changes in volume. This explains differences between the (in vivo) MRI volumes and the (ex vivo) necropsy volumes.

The segmentation of the MRI slices however is a reliable method to assess the volume of the gland.

We were able to show that this assessment produces robust results, when being performed by trained investigators. Furthermore assessing regions within the gland is also a reasonable approach to observe and monitor the responses of the different substructures within the prostate individually. We were able to demonstrate by MRI analysis that during treatment with finasteride the glandular tissue shows the strongest treatment response compared to the periurethral region. These results confirm the histological findings of Laroque et al. (3). MRI is capable of differentiating and quantifying these substructures. In addition to the non-invasive assessment of the size of the prostate, our analysis allowed us to examine also changes within the gland that are not necessarily represented by volume changes. Therefore, zonal MRI volumetric measurements are a valuable tool to monitor treatment effects of pharmacotherapy.

## References:

1. Pavelic, J. et al. (2003), Urology 62(4), 607-613
2. McAuliffe, MJ et al. (2001), IEEE CBMS, 381-386.
3. Laroque, P.A. et al (1994), The Prostate 24, 93-100

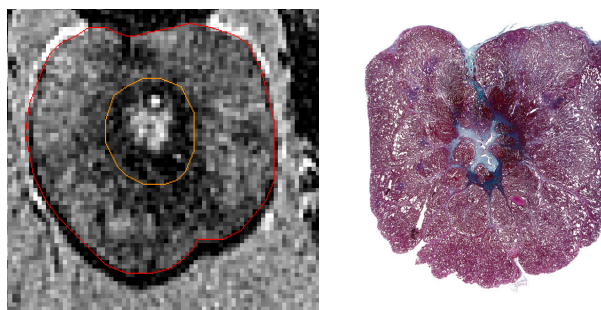


Fig. 1: Correlation of a MR image with a corresponding histologic slide. The volume inside the red VOI is the total volume, the volume within the orange VOI is the periurethral volume and the donut shaped volume between the red and the orange volume is the glandular volume. , histologic slide: Masson Trichrome

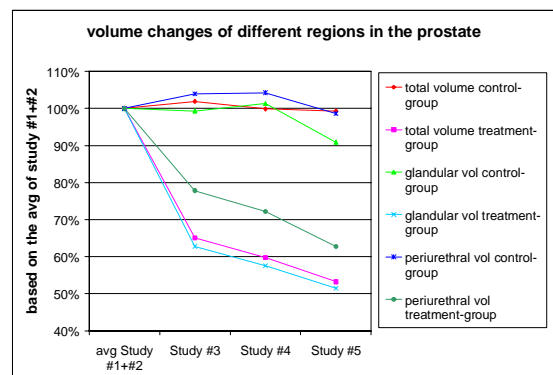


Fig. 2: The average volumes of the different areas during the treatment studies #3, #4 and #5 in relation to the average of the two pre treatment studies #1 and #2.