

## Altered Adipose Tissue Deposition after Extremely Preterm Birth

S. Uthaya<sup>1</sup>, E. Thomas<sup>2</sup>, G. Hamilton<sup>2</sup>, N. Modi<sup>1</sup>, J. D. Bell<sup>2</sup>

<sup>1</sup>Division of Obstetrics, Gynaecology and Paediatrics, Hammersmith Hospital, Imperial College London, London, United Kingdom, <sup>2</sup>Robert Steiner MRI Unit, Imaging Sciences Department, Clinical Sciences Centre, Hammersmith Hospital, Imperial College London, London, United Kingdom

**Background:** Small size at birth has been linked to adult onset of morbidities including obesity, insulin resistance and cardiovascular disease [1]. Many of the epidemiological studies that have demonstrated this link have not distinguished between prematurity, growth restriction and genetic potential as causes of small size. Different adipose tissue compartments have different metabolic functions and intra-abdominal adiposity is associated with insulin resistance [2]. It is not clear when abnormal patterns of adiposity are established in predisposed individuals. Body composition studies in infants have traditionally used indirect methods of quantifying adipose tissue and have been unable to distinguish specific adipose tissue depots. We have used magnetic resonance imaging (MRI) to assess total and depot specific adipose tissue in preterm babies at age term equivalent with term-born babies and to explore the possible determinants of adipose tissue deposition.

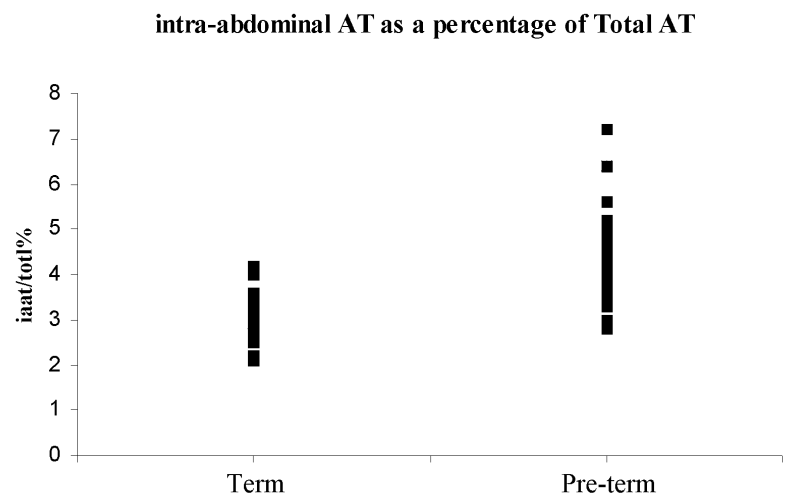
**Methods:** Whole body MRI was used to determine the distribution and content of adipose tissue in preterm infants (>32 weeks of gestation) at term age equivalent and appropriately grown term infants. Infants were scanned in natural sleep in the supine position without sedation. MR images were acquired on a Phillips 1.5T system using a rapid T1-weighted spin-echo sequence (TR600/TE16), a 256 x 256 matrix, and 5 mm slice thickness, combined with the serial isocentre technique, in which the subject is moved through the magnet, allowing full body imaging [3]. Inter-slice distance was 5mm. Images were analysed using a commercially available software programme, *SliceOmatic* (Tomovision, Montreal) and adipose tissue regions quantified. Parametric and non-parametric tests were used as appropriate to compare the two groups of babies. Results are expressed as median and range.

**Results:** Twenty four term and twenty eight preterm infants underwent whole body adipose tissue imaging. At term preterm infants were significantly lighter than the term born infants (preterm 2.52 kg (1.84 - 4.77), term 3.24 kg (2.63 - 3.88)  $p < 0.0001$  (95% CI, 0.48 to 0.88). However, total adipose tissue mass expressed as a percentage of body weight was not significantly different between the two groups (preterm 21.2% (15.5 - 25.2), term 22% (18.1 - 32.1)  $p = 0.63$ ; (95% CI, -2.41 to 1.76). This masked a highly significant difference in the distribution of adipose tissue between the subcutaneous and intra-abdominal compartments. The preterm infants had less adipose tissue in the subcutaneous compartment than the term infants and a significantly higher proportion of adipose tissue in the intra-abdominal compartment. Subcutaneous adipose tissue expressed as a percentage of total adipose tissue in preterm infants was 89% (80.7 - 91.2), and term infants 92% (90.5 - 93.5)  $p < 0.0001$  (95% CI, 2.07 to 3.8). Intra-abdominal adipose tissue as a percentage of total adipose tissue in preterm infants was 4.4% (2.8 - 7.2) and in term infants 2.9% (2.1 - 4.2)  $p < 0.0001$  (95% CI -1.79 to -0.96).

**Conclusions:** Whole body MR adipose tissue imaging during natural sleep is feasible and practicable in preterm infants. Our preliminary observations indicate that there is preferential deposition of adipose tissue in the intra-abdominal compartment in preterm babies at term. Further exploration is required to identify the determinants and the short and long-term metabolic implications for the later health of preterm babies

### References

1. Barker, D. J. et al. *Lancet* (1989) **2.8663**: 577-80.
2. Wajchenberg, B. L. et al. *Horm. Metab Res* (2002) **34**: 616-21.
3. Harrington T, Thomas EL, Modi N et al. *Lipids* (2002) **37**:95-100



**Figure 1:** Graph showing intra-abdominal adipose tissue as a percentage of total adipose tissue in preterm and term infants