

Assessment of Lung Development using Hyperpolarized Helium-3 Diffusion MR Imaging

T. A. Altes¹, J. P. Mugler, III¹, J. Mata¹, J. Benjamin-Watkins¹, S. R. Herlihy², E. E. de Lange¹, J. R. Brookeman¹
¹Radiology, University of Virginia, Charlottesville, VA, United States, ²University of Virginia, Charlottesville, VA, United States

Introduction

Hyperpolarized helium-3 (H3He) is a gaseous contrast agent that, when inhaled, permits MR imaging of the lung airspaces. The apparent diffusion coefficient (ADC) of inhaled H3He provides a measure of the size and morphology of the distal airspaces within the lung. Enlarged airspaces have been detected using H3He diffusion imaging in animal models of emphysema and in humans with emphysema (1-4). In normal adults, it has been questioned whether there is a slight trend toward increasing mean ADC values with advancing age (5). To our knowledge, the normal H3He ADC findings in the pediatric age group have not been reported previously. It is widely believed that humans grow new aveoli from a few weeks before term birth until approximately 8 years of age, after which the alveoli are thought to enlarge as the lungs increase in volume, but no new alveoli are formed (6). It is therefore expected that in the pediatric age group, the increase in alveolar size with increasing age will be reflected in an increase in H3He ADC with age.

Methods

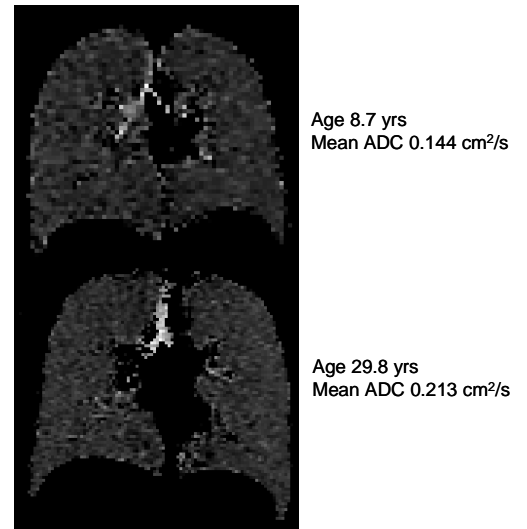
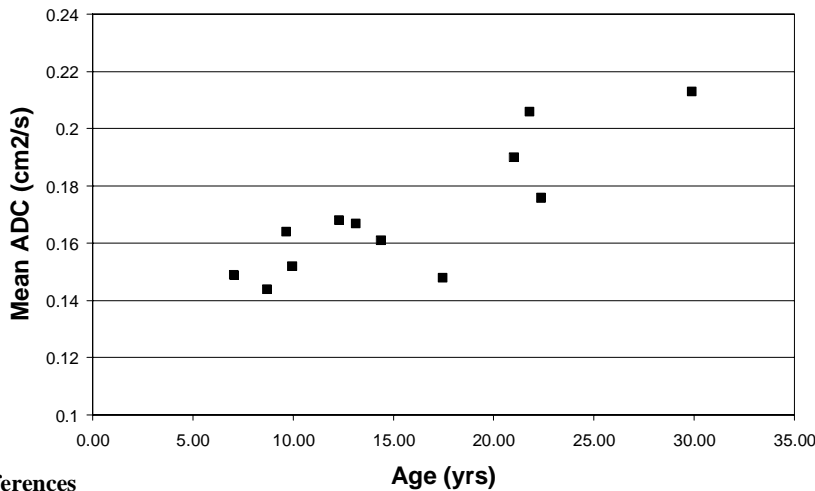
Twelve healthy subjects underwent H3He diffusion MR imaging on a 1.5T whole-body MR scanner (Magnetom Vision, Siemens Medical Solutions). The age range was 7 to 29 yrs (mean 15.6, standard deviation 6.9 yrs). Subjects were positioned supine in the MR scanner, and starting from maximum expiration, subjects inhaled a mixture of approximately 30% H3He and 70% nitrogen to a total volume of approximately 1/3 of the subject's forced vital capacity (FVC). During the subsequent breath hold, contiguous coronal diffusion images were acquired covering the whole lung volume using a FLASH-based diffusion sequence (TR/TE, 11/6.7 ms; FA, 7°; matrix, 80 x 128; FOV, 37 x 42 cm, slice thickness 20 mm, b-values, 0 and 1.6 s/cm²). The length of the breath hold depended on the number of images required to cover the entire lung volume but was typically less than 15 sec. The mean and standard deviation of the ADC for all of the slices in a study was computed for each subject.

Results

All 12 of the subjects had homogenous appearing ADC maps. As has been noted previously in normal subjects, the ADC values were slightly higher in the anterior than the posterior slices (7). There was a strong trend toward increasing mean ADC values with increasing age as shown in the figure below ($r=0.85$). The average of the mean ADC was 0.16 cm²/s for subjects under age 18 yrs and 0.20 cm²/s for those over age 18 yrs ($p<0.01$). Comparing the mean ADC with other measures of maturation or lung volume gave correlation coefficients of 0.74 with height, 0.64 with weight, 0.76 with FVC in liters, 0.81 with the predicted FVC based on the subject's age and height, and 0.34 with the percent predicted FVC. With the standard deviation of the ADC, there was no trend with age ($r=0.32$), and the average of the standard deviation of the ADC was 0.068 cm²/s for subjects age less than 18 years and 0.72 cm²/s for those over 18 yrs ($p=0.36$).

Discussion

We found that the mean ADC increases with age in the pediatric population and that the mean ADC is lower in the pediatric age group than in young adults suggesting that the pediatric subjects had smaller airspaces than the young adults. The variability of the airspace structure, as measured by the standard deviation of the ADC values, did not change with age, as expected. Given that the alveoli are thought to increase in size as the lungs increase in size from late childhood until adulthood, H3He diffusion MR lung imaging appears to be able to detect this normal maturation process of the lungs. Having detected normal maturation, it is possible that H3He diffusion MR imaging may be able to detect alterations in this process that are the result of chronic lung diseases of childhood.



References

1. Chen XJ, Hedlund LW, Moller HE, et al. Proc Natl Acad Sci 2000; 97:11478-81.
2. Cremillieux Y, Ruiz-Cabello J, Peces-Barba G, et al. In: Proc Intl Soc Magn Reson Med, 10th Meeting, 2002; 757.
3. Saam BT, Yablonskiy DA, Kodibagkar VD, et al. Magn Reson Med 2000; 44:174-179.
4. Salerno M, de Lange EE, Altes TA, et al. Radiology 2002; 222:252-60.
5. Brookeman JR, Mugler III JP, Knight-Scott J, et al. Eur Radiol, 1999;9:B21
6. Thurlbeck WM, Thorax. 1982;37:564-71
7. Salerno M, Brookeman JR, de Lange EE, et al. In Proc Intl Soc Magn Reson Med, 8th Meeting, 2000, 2195.

Acknowledgements This work was supported by the Commonwealth of Virginia Technology Research Fund (Grant No. IN2002-01), Siemens Medical Solutions, and Amersham Health.