

# Early laminar organization of the human cerebrum demonstrated by automatic segmentation of diffusion tensor MR images in extremely premature infants

J. Carballido-Gamio<sup>1</sup>, P. Mukherjee<sup>1</sup>, L. C. Maas<sup>1</sup>, S. Veeraraghavan<sup>1</sup>, S. P. Miller<sup>1</sup>, S. C. Partridge<sup>1</sup>, R. G. Henry<sup>1</sup>, A. J. Barkovich<sup>1</sup>, D. B. Vigneron<sup>1</sup>

<sup>1</sup>University of California, San Francisco, San Francisco, California, United States

## Introduction

Diffusion tensor imaging (DTI) is a non-invasive technique that probes diffusion of water molecules at a microstructural level. DTI has been used to reveal the transient early laminar architecture of the developing fetal mouse brain *ex vivo* [1], many features of which are not apparent on conventional MR imaging. The purpose of this work is to present an automatic segmentation technique to delineate the early cerebral laminar organization of premature human newborns *in vivo*, taking advantage of the multi-channel information yielded by DTI. The segmentation technique is based on a Mamdani-type fuzzy inference system (FIS) [2].

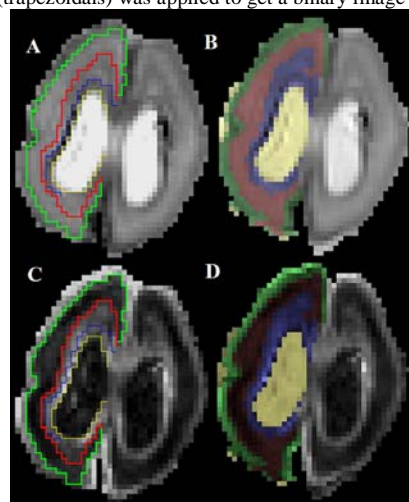
## Methods

Two extremely premature infants born at estimated gestational ages (EGAs) of 24 and 25 weeks were imaged at 1.5 T (Signa EchoSpeed scanner; GE Medical Systems, Milwaukee, WI) with a high sensitivity neonatal head coil incorporated into an MR-compatible incubator [3]. The infants were imaged at EGAs of 25 and 27 weeks (Subjects 1 and 2, respectively). DT images were acquired with a multi-repetition, single-shot echoplanar technique (TR/TE 7000/99.5 ms, slice thickness 3 mm, no gap, 3 NEX, 36 x 18 cm FOV, 256 x 128 acquisition matrix, in-plane resolution 1.4 mm x 1.4 mm, b=600 s/mm<sup>2</sup>), transferred to a workstation and registered to the image with b=0 s/mm<sup>2</sup> prior to tensor calculation. Maps of the rotationally-invariant apparent diffusion coefficient (ADC) and fractional anisotropy (FA) were calculated, and manual segmentation was performed taking as a reference the *ex-vivo* work presented in [4]. Based on the pattern of ADC and FA values observed at the different cerebral lamina, an automatic segmentation technique based on fuzzy logic was developed in MATLAB (The Mathworks, Inc. Natick, MA). First, ADC values were clustered into low, medium, and high ADC groups using fuzzy c-means to get an initial estimate of the ADC value distribution: CSF (high ADC), subplate (medium ADC), deep-to-subplate and cortical layers (low ADC). CSF pixels were removed from subsequent segmentation, and remaining pixels were clustered according to their FA values into subplate (low FA), deep-to-subplate and cortical layers (medium FA), and noise (high FA). Then a Mamdani-type FIS with two inputs (FA and ADC pixels different from CSF) and 1 output was built to segment the subplate. Each input was fuzzified by two Gaussian membership functions which were created based on the means and standard deviations of the low and medium ADC and FA groups, and the segmentation was accomplished with the following two rules based on observations of the manual segmentation: 1. If the ADC is medium and the FA is low, then the pixel is subplate. 2. If the ADC is low and the FA is medium, then the pixel is non-subplate. Because the output was continuous, an automatic threshold equal to the point of intersection of the 2 output membership functions (trapezoidals) was applied to get a binary image representing subplate pixels in its majority. Based on a-priori knowledge about the size of the subplate, a connectivity labeling technique was applied to the binary image, and the largest group was selected as the final subplate layer. Remaining pixels were then segmented based on their position relative to the subplate into cortical and deep-to-subplate layers.

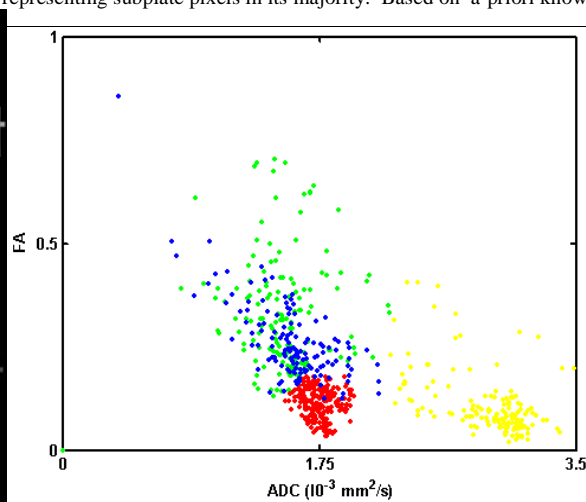
labeling technique was applied to the binary image, and the largest group was selected as the final subplate layer. Remaining pixels were then segmented based on their position relative to the subplate into cortical and deep-to-subplate layers.

## Results

Figure 1 shows side by side the manual and automatic segmentation results of the right cerebral hemisphere of Subject 1, applied to both ADC (A,B) and FA (C,D). The color intensity in the automatically segmented images has been weighted according to the ADC or FA values. An inverse weighting for CSF on the FA map has been used to facilitate visualization. A scatter plot of ADC and FA pixel values in the images of Figure 1, with pixel classification by the automatic segmentation algorithm, is shown in Figure 2: high ADC values for CSF (yellow); medium ADC and low FA values for subplate (red); low ADC and medium FA for the cortical (green) and deep-to-subplate layers (blue), which are distinguished from each other by their position superficial and deep to the subplate, respectively.



**Figure 1.** Premature newborn imaged at 25 weeks EGA. ADC map manually (A) and automatically segmented (B). FA map manually (C) and automatically segmented (D).



**Figure 2.** Scatter plot of FA vs ADC, where each point represents a pixel from the FA and ADC images of Fig. 1 that has been automatically segmented. **Color code for Fig. 1 and 2:** Green=cortical layer; red=subplate; blue=deep-to-subplate; yellow=CSF.

## Discussion and Conclusions

In this work we have developed an automatic segmentation technique based on fuzzy logic to delineate the early laminar organization of the premature human brain depicted by DTI, but not by conventional T1- or T2-weighted images. Images were segmented into a cortical layer, a subplate layer, and a deep-to-subplate layer that includes the intermediate zone, subventricular zone, periventricular zone, and germinal matrix. Further improvements to the algorithm are necessary to deal with germinal matrix hemorrhages, and to further subdivide the deep-to-subplate layer into its constituents. Possible improvements include the incorporation of additional DTI parameters, such as the eigenvalues and eigenvectors of the tensor, or information from conventional high-resolution MR images. Automatic segmentation of the different lamina of the developing human cerebrum will enable volumetric studies to better understand and characterize normal and abnormal maturation during early human brain development.

## References

- [1] S. Mori, R. Itoh, J. Zhang, W.E. Kaufmann, P.C.M., van Zijl, M. Solaiyappan, P. Yarowsky. "Diffusion tensor imaging of the developing mouse brain." *Magn Reson Med* 46, 18-23. 2001.
- [2] E.H. Mamdani, S. Assilian, "An experiment in linguistic synthesis with a fuzzy logic controller." *International Journal of Man-Machine Studies* 7, 1-13. 1975.
- [3] C.L. Dumoulin, K.W. Rohling, J.E. Piel, C.J. Rossi, R.O. Giaquinto, R.D. Watkins, D.B. Vigneron, A.J. Barkovich, N. Newton, "An MRI compatible neonate incubator." *Concepts in Magnetic Resonance (Magn Reson Engineering)* 15, 117-128, 2002.
- [4] I. Kostovic, M. Judas, M. Rados, P. Hrabac. "Laminar organization of the human fetal cerebrum revealed by histochemical markers and magnetic resonance imaging." *Cereb Cortex* 12, 536-44. 2002.

**Acknowledgements** The authors acknowledge funding support from the NIH (R01-NS40117, P50-NS35902, and R21-NS40382).