

# Quantitative volumetric MR imaging analysis to assess the effect of prematurity and white matter injury on neonate brain development

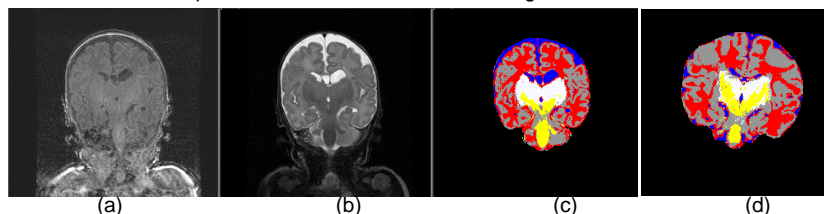
T. E. Inder<sup>1,2</sup>, D. K. Thompson<sup>2</sup>, M. Pavlovic<sup>2</sup>, H. X. Wang<sup>2</sup>, R. W. Hunt<sup>1</sup>, S. K. Warfield<sup>3</sup>, G. F. Egan<sup>2</sup>

<sup>1</sup>Royal Children's Hospital, Melbourne, Victoria, Australia, <sup>2</sup>Howard Florey Institute, Melbourne, Victoria, Australia, <sup>3</sup>Brigham and Women's Hospital, Harvard Medical School, Boston, MA, United States

**Introduction:** Perinatal events produce long-term disturbances in cerebral development and these disturbances may account for the later cognitive and motor deficits that occur in preterm infants. However, the aetiology of these disturbances is still poorly understood and a better understanding of the contributing factors to these neurodevelopmental abnormalities is required. In this study MR imaging and volumetric analysis techniques were used to quantitatively measure cerebral tissue volumes within the preterm brain. In particular, we have investigated the effect of birth weight, gestational age, gender and degree of white matter injury on premature infant brain development. In addition we have carried out regional volumetric analysis of brain images in order to determine the regional variations of cerebral tissue types and severity of white matter injury.

**Method:** A prospective observational cohort study in full term and preterm (< 32 weeks or < 1250 grams) infants was conducted at the Royal Women's Hospital Melbourne. Imaging was performed with a 1.5-Tesla General Electric MRI scanner. 3D MRI and image processing algorithms were used to perform quantitative volumetric analysis of neonate brain images at term corrected age. T1 spoiled gradient recalled (SPGR) sequences (1.5mm coronal slices, flip angle 45°, repetition time 35ms; echo time 9ms; field of view 18cm; matrix= 256 x 256) and dual-echo (proton density (PD) and T2-weighted) spin echo sequences (3mm coronal; TR= 4000msec; TE 60 / 160msec; FOV 18cm; matrix 512 x 512, interleaved acquisition) were acquired (Figure 1a,b). The image processing algorithms used were designed to reduce imaging system noise, align T1 and T2 images and to segment the imaged volume<sup>1</sup>. The segmentation method applied is a spatially varying statistical classification in which a 40-week infant brain image is used as an anatomical template to correct the result of tissue classification (Figure 1c,d). Average cerebral tissue volumes were calculated for cortical gray matter, unmyelinated white matter, myelinated white matter, basal ganglia (subcortical gray matter) and cerebrospinal fluid (CSF). Statistical analysis was performed on data grouped according to birth weight, gestational age, gender, and the severity of white matter injury based on qualitative image analysis {WMI1=normal (n=42), 2=mild abnormality (n=56), 3=moderate abnormality (n=15), 4=cystic abnormalities (n=5)}. Comparison of total and regional brain volumes of different tissue classes was performed by dividing the brain into hemispheres. Each hemisphere was further divided into 8 anatomical sectors (dorsal prefrontal, orbitofrontal, premotor, subgenual, sensorimotor, midtemporal, parieto occipital and inferior occipital with cerebellum)<sup>2</sup>, using the axial plane encompassing anterior commissure-posterior commissure (AC-PC) line and 3 limiting coronal planes. The first coronal plane was positioned at the genu of corpus callosum, the second passed through the anterior border of AC, and the third through the PC.

**Results:** 21 term and 118 preterm infants were recruited into this study. There were significant differences in cerebral structure between the preterm infants and term born controls. Preterm infants compared with full term infants had significantly lower cortical gray matter volumes (mean  $\pm$  SD: Preterm 151  $\pm$  42cc; Term 172  $\pm$  38cc;  $p < 0.04$ ) and subcortical gray matter (16.0  $\pm$  5.8cc; 20.0  $\pm$  6.8cc;  $p < 0.01$ ). Correspondingly, total intracranial CSF volume was significantly greater (42  $\pm$  21cc; 28  $\pm$  13cc;  $p < 0.0002$ ) (Figure 1c,d). In addition correcting as % total intracranial volume, preterm infants had relatively less gray matter than term born infants (PreTerm 38.6%; Term 39.9%), less subcortical gray matter (PT4.1%; T4.8%), and more CSF (PT10.8%; T6.5%). As the severity of white matter injury increased, absolute volumes of cortical gray matter, unmyelinated WM and basal ganglia decreased (total tissue: WMI1 399  $\pm$  62cc; WMI4 335  $\pm$  78cc) while CSF increased (WMI1 37  $\pm$  17cc; WMI4 69  $\pm$  35cc). The most significant tissue reduction in brain volumes occurred for the basal ganglia (WMI1 16.0  $\pm$  5.8cc; WMI4 9.0  $\pm$  3.6cc;  $p < 0.008$ ). Premature males had larger absolute brain volumes than premature females (Male 409  $\pm$  7cc vs Female 369  $\pm$  8cc;  $p < 0.005$ ). There was no significant regional measure of brain development which correlated with birth weight or gestational age. Prematurely born infants with WMI and preterm infants had significantly decreased regional volumes of cerebral tissue types, namely motor and occipital areas for gray matter (22.5  $\pm$  3.9%; 33.5  $\pm$  4.2%) in comparison to the term born infants (35.0  $\pm$  3.5%; 42.5  $\pm$  4.0). Myelinated white matter volumes were significantly reduced in motor (3.8  $\pm$  0.3%; 1.6  $\pm$  0.2%) and occipital areas (0.8  $\pm$  0.2%; 0.6  $\pm$  0.1%) for the term and preterm infants with WMI, respectively. A marked increase in CSF was found in premature infants with WMI in comparison to the term infants for all regions.



**Figure 1:** Spgr (a) and T2 weighted (b) images. Segmented image of a WMI preterm infant (c) and full term infant (d). Tissue types: cortical GM (gray); unmyelinated WM (red); CSF (blue); myelinated WM (yellow); and basal ganglia (white).

**Conclusion:** The premature infant demonstrates significant alterations in brain structure on quantitative MR imaging by term equivalent. Combined regional volumetric analysis with structural neuroimaging techniques enables investigation of macroscopic anatomical organization and regional distribution of cerebral tissue types, demonstrating maximal reduction in gray matter and myelinated WM in the sensory motor and occipital regions in preterm infants. Disturbance in cerebral development in motor portions of the brain for preterm children and WMI infants may account for predisposition to cerebral palsy and other motor disturbances in these infants. Implementation of magnetic resonance imaging coupled with quantitative volumetric analysis provides a reliable tool for assessing tissue alterations in brain volumes and regionally specific abnormalities.

<sup>1</sup> Warfield SK, Kaus M, Jolesz FA, Kikinis R. Adaptive, template moderated, spatially varying statistical classification. *MIA Med Imag Analysis*. 2000 Mar;4(1):43-55.

<sup>2</sup> Peterson BS, Vohr B, Staib LH, et al. Regional Brain Volume Abnormalities and Long-term Cognitive Outcome in Preterm Infants. *JAMA J Am Medical Assoc*. 2000 Oct;284(15):1939-47.