

Absolute choline concentration in 1H MR spectroscopy and diffusion-weighted MR imaging at 3.0T for the diagnosis and monitoring of therapeutic effect of hepatocellular carcinoma before and after chemo

C. Chen¹, G-C. Liu¹, T. Jaw¹, C. Li²

¹Department of Medical Imaging, Kaohsiung Medical University Chung-Ho Memorial Hospital, Kaohsiung, Taiwan, ²Faculty of Medical Radiation Technology, Kaohsiung Medical University, Kaohsiung, Taiwan

Synopsis:

To evaluate the diagnosis and therapeutic effect of patients with large Hepatocellular carcinoma (HCC) before and after transarterial chemoembolization (TACE) by absolute choline concentration on ¹H MRS and the ADC value with DWMR images. Absolute choline concentration on ¹H MRS and DWMR image could be useful methods for diagnosis and monitoring the therapeutic response to TACE for HCC.

Introduction:

The imaging diagnosis of HCC and monitoring of its therapeutic effect are still challenging. MRS has been proved valuable in the diagnosis of tumors in brain, prostate, breast and uterus, as well as in the evaluation of tumor recurrence in head and neck malignancies. ADC value has been used effectively in the assessment the response of chemoembolization in rabbit hepatic tumor model. We hypothesized that ¹H MRS and DW/MR imaging may help the diagnosis and monitoring of the therapeutic response of HCC.

Material and Methods:

Twenty patients with large HCC (> 3cm in diameter) were examined with single-voxel MRS (Probe-P) using body coil and spin-echo echo-planar sequence (SE-EPI) (b, 0 and 500 sec/mm²) MR imaging at 3.0T MR scanner (Signa VH/I, GE). Eight of the 20 HCCs received the studies before and after TACE. We also examined seven patients with hemangiomas and five patients with metastases using the same protocol as a control group.

The spectroscopic data were analyzed by physicists blind to clinical data with commercially available soft ware (SAGE 7.2, GE Medical Systems). The absolute concentration of choline was measured by external phantom replacement method at 3.2 ppm choline peak. ADCs were calculated for all lesions with commercially available soft ware in an imaging workstation (Functool & AW 4.0; GE Medical systems). Kruskal-wallis test was used to compare these data. Wilcoxon signed rank test is used for comparing the choline change of HCCs before and after TACE.

Results:

The mean choline concentration for HCC, hemangioma and metastases are 3.23mM±3.19, 0.20mM±0.28, 0.95mM±0.64 and ADCs for these lesions are 1.70x10⁻³mm²/sec±0.31, 2.77x10⁻³mm²/sec±0.70, 1.64x10⁻³mm²/sec±0.48, respectively. Statistically significant differences on ADC exist between hemangioma and malignant tumors (HCC and metastases) (p<.01). There is significant increase of choline concentrations in HCC as compared to hemangioma and metastases (p<.01).

The mean choline concentration for 8 HCCs post TACE decreased from 4.8mM±3.68 to 0.91mM±1.14(p<.01). The mean ADC for 8 HCCs post TACE increased from 1.8x10⁻³ mm²/sec±0.35 to 2.18x10⁻³mm²/sec±0.31 (p<.01).

Discussion:

Elevation of choline peak in HCC may be due to increased membrane phospholipids biosynthesis and is an active marker for cellular proliferation. Relatively low choline peak in metastasis is possibly due to much necrotic area contamination. Decrease choline peak and increase ADC value in post TACE of HCC can be explained by the presence of greater amounts of extracellular water within the necrotic region caused by cell lysis and leakier cell membranes.

Conclusion:

1. DW MR imaging is useful for differentiating HCC from hemangioma and is nonsignificant between HCC and metastases.
2. ¹H MR spectroscopy may be feasible in differentiating HCC from the other hepatic tumors.
3. Absolute choline concentration on ¹H MRS and ADC value could be useful methods for monitoring therapeutic response to TACE for HCC.

Reference:

1. Taouli B, Radiology 2003, 226: 71-78.
2. Geschwind, Jean-Francois H. et el; J Vase Inter Radiol, Vol. 11(10). 2000, 1245-1255.
3. Maheshwari SR, AJNR 21: 1930-1935, 2000.

Case	Pre Cho (mm)	Post Cho (mm)	Pre ADC (mm ² /sec)	Post ADC (mm ² /sec)
1	5.8	1.8	2.14 x10 ⁻³	2.34 x10 ⁻³
2	9	1.6	1.75 x10 ⁻³	2.30 x10 ⁻³
3	0.5	0	1.61 x10 ⁻³	1.89 x10 ⁻³
4	1.3	0.1	2.35 x10 ⁻³	2.70 x10 ⁻³
5	8.8	0	1.55 x10 ⁻³	2.23 x10 ⁻³
6	3.1	0.4	1.53 x10 ⁻³	1.80 x10 ⁻³
7	1.3	0.2	2.10 x10 ⁻³	2.31 x10 ⁻³
8	8.6	3.1	1.39 x10 ⁻³	1.87 x10 ⁻³
mean±SD	4.8±3.68	0.91±1.14	1.8 x10 ⁻³ ±0.35	2.18 x10 ⁻³ ±0.31

P<.01

P<0.1

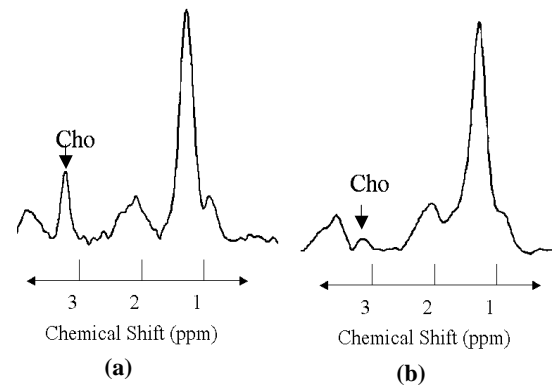


Table 1: The value of ADC and choline change in HCC pre- and post- TACE. Fig1. MRS of HCC with pre-and post-TACE show choline peak at 3.2ppm and choline concentration from 4.2mM decrease to 1.2mM