

Vacuum-assisted iMRI-guided percutaneous core biopsy of small breast lesions: first experience with a vertically open 0.5T scanner in the prone or supine position

G. L. Hwang¹, D. M. Ikeda¹, R. L. Birdwell¹, B. L. Daniel¹

¹Stanford University Medical Center, Stanford, CA, United States

SYNOPSIS

We describe a novel method of vacuum-assisted core breast biopsy in a 0.5T open MR using a freehand approach. The patients can be positioned prone, allowing medial or lateral access to lesions, or supine, allowing an anterior approach. Biopsies of 17 lesions in 14 patients have yielded one malignant diagnosis. No discordant diagnoses were found in five patients who later underwent surgical excision of the lesion sites. This method provides a minimally invasive alternative for sampling suspicious lesions detected on MRI. It allows a three-dimensional approach to targeting lesions and allows sampling of multiple or difficult-to-access lesions.

INTRODUCTION

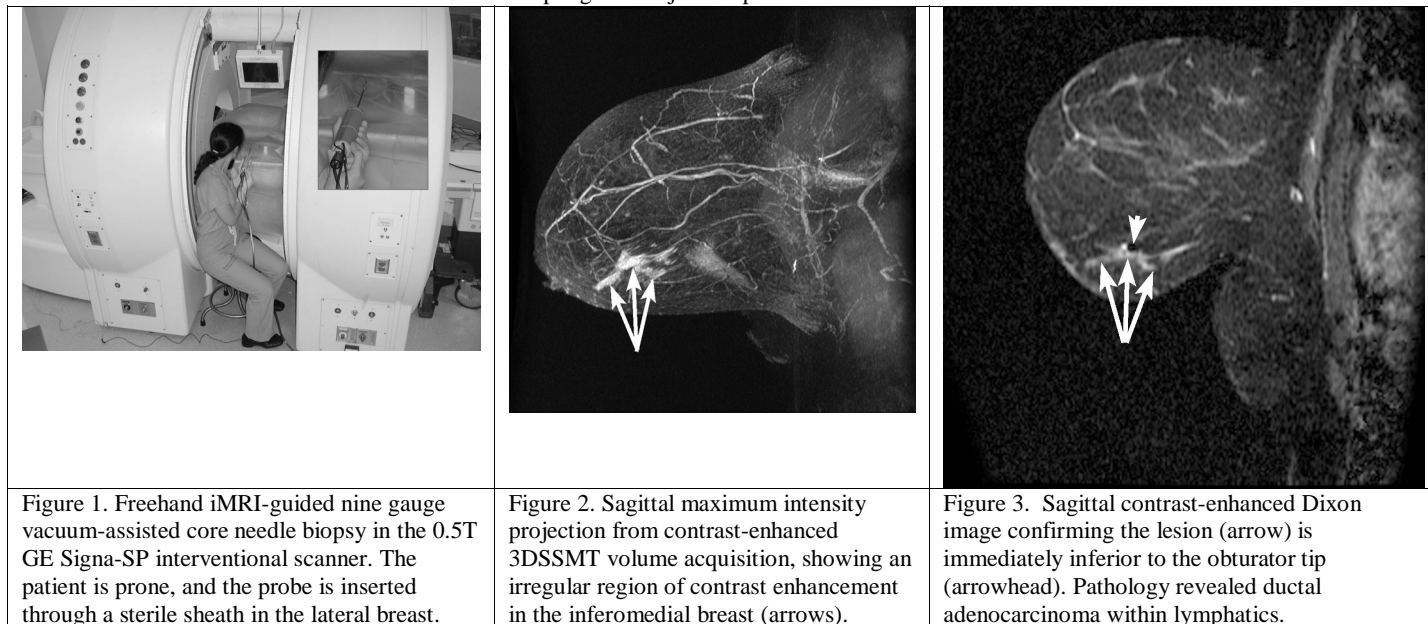
A suspicious lesion detected on breast MRI requires tissue sampling to exclude malignancy. Excisional biopsy with MR-guided wire localization, the standard of care for lesions not seen by ultrasound or mammography, is costly and invasive. We describe a novel method of sampling such lesions with a new, MR-compatible vacuum-assisted core breast biopsy device in an open MR environment using a freehand approach (Fig. 1).

METHODS

Biopsies were performed on 17 lesions in 14 patients. The technique is a modification of previously described techniques (1,2). Lesions were considered suspicious if they demonstrated rapid initial enhancement on dynamic MR imaging. Thirteen patients were placed in the prone position in a vertically open magnet using a dedicated breast coil. Nine patients were sampled from a lateral approach, and four were positioned slightly oblique and sampled from a medial approach. One patient with an implant was placed in the supine position with a surface coil and sampled from an anterior approach. Diagnostic MRI images obtained in a 1.5T magnet were initially reviewed to guide biopsy approach (Fig. 2). The skin entry site was marked with an MR-compatible marker, the breast imaged, and the biopsy site determined by architectural features. Using local anesthesia, an introducer sheath was inserted over a sharp trocar to the expected location of the lesion, with the trocar tip forming a tract beyond the lesion. An MR-compatible obturator was placed within the sheath, and contrast was given to confirm lesion localization (Fig. 3). A nine-gauge MR-compatible vacuum-assisted biopsy probe was then inserted through the sheath and samples obtained.

RESULTS

One ductal carcinoma with angiolymphatic involvement was detected. The remaining biopsies demonstrated fibrocystic change ($N=9$), benign breast parenchyma ($N=4$), a fibroadenoma ($N=1$), scar and reactive changes from a prior core biopsy ($N=1$), and fibroadipose tissue without breast parenchyma ($N=1$). Five patients underwent surgical excision of the core biopsy sites. The patient with ductal carcinoma underwent a mastectomy, confirming malignant findings. Three wire-localized excisional biopsies and one prophylactic mastectomy were performed, which confirmed benign diagnoses. The remaining patients will receive a six-month follow-up diagnostic breast MRI. Two biopsies (12%) resulted in minor complications: one moderate hematoma and one inadvertent skin sampling. No major complications were encountered.



DISCUSSION

We report a novel, freehand method of obtaining tissue in patients with suspicious lesions seen by MRI. This minimally invasive method allows substantial tissue sampling while providing flexibility in needle positioning, a three-dimensional approach to needle guidance, the ability to sample lesions without moving the patient from within the magnet, the ability to sample multiple lesions, and the ability to access difficult lesions.

REFERENCES

1. Daniel BL, Birdwell RL, Butts K, et al. Freehand iMRI-guided large-gauge core needle biopsy: a new minimally invasive technique for diagnosis of enhancing breast lesions. *J Magn Reson Imaging* 2001; 13:896-902.
2. Daniel BL, Birdwell RL, Ikeda DM, et al. Breast localization: a freehand, interactive MR imaging-guided technique. *Radiology* 1998; 207:455-463.