

Altered Myocardial Strain Patterns as a Novel Mechanism for Pacing-Induced Ventricular Remodeling: an MRI Tagging Study

J. Zhong¹, D. Jeyaraj², C. Flask³, L. Wilson², D. S. Rosenbaum², X. Yu¹

¹Department of Biomedical Engineering, Case Western Reserve University, Cleveland, OH, United States, ²Heart & Vascular Research Center, Case Western Reserve University, Cleveland, OH, United States, ³Department of Radiology, Case Western Reserve University, Cleveland, OH, United States

Introduction

Ventricular electrical remodeling (VER) is a persistent change in electrophysiological properties of myocardium in response to changes in heart rate or activation sequence (i.e. pacing). It has substantial pathophysiological consequences including exacerbated heart failure and increased cardiac mortality. Altering the normal sequence of electrical activation of the heart by ventricular pacing induces profound and long lasting T wave changes ascribed to "T-wave memory", which is a common clinical manifestation of VER. VER is also associated with prolongation of action potential duration (APD). However, the mechanisms underlying APD prolongation and their role in T-wave memory are poorly understood. Improved understanding of the mechanism underlying VER will provide important insights to the pathophysiology of heart disease, as well as novel strategies to prevent it.

In this study, we seek to demonstrate the underlying mechanism for pacing-induced ventricular remodeling by segmented myocardial strain analysis using MRI tagging.

Materials and Methods

Animal Preparation Adult male mongrel dogs (n=5) were anaesthetized with propofol (10mg/kg), intubated, ventilated and maintained on inhalational isoflurane. Following lateral thoracotomy, pacing leads were implanted on the epicardial surface of anterior and posterior LV wall, as well as the right atrium(RA).

MR Imaging The dogs were scanned on a 1.5T Siemens Sonata scanner (Siemens Medical Solutions, Erlangen, Germany). Body-array and spine-array coils were used for image acquisition. ECG triggered, horizontal and vertical tagged short-axis MR images were acquired at basal, mid-ventricular, and apical levels with anterior pacing, posterior pacing, and atrial pacing. The tagging sequence was followed by T₁-weighted FLASH sequence with the following imaging parameters: field of view, 12.5 cm × 25.0 cm; flip angle, 20°; matrix size, 128×256; tagging resolution, 4 mm; slice thickness, 8 mm. Repetition time was adjusted such that fourteen to nineteen frames were acquired per cardiac cycle.

Image Analysis Images were analyzed using a MATLAB-based Cardiovascular MR Image Analysis Tool (CVMRI). Epicardial and endocardial contours were traced interactively using B-spline interpolation with 8 control points. Intersecting tag points were tracked semi-automatically with HARP-based approach (1). Subsequently, circumferential and radial strains in septum, posterior, lateral, and anterior segments of left ventricle were calculated by 2D homogenous strain analysis.

Results

Figure 1 shows representative short-axis images of a dog heart paced from anterior and posterior of the LV wall, superimposed with colored circumferential strain maps. Our analysis shows that circumferential and radial strains were similar between left ventricular segments during sinus rhythm (Figure 2, P=0.64).

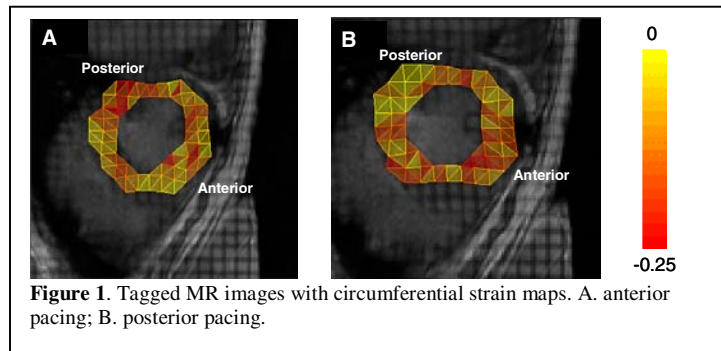


Figure 1. Tagged MR images with circumferential strain maps. A. anterior pacing; B. posterior pacing.

However, during anterior LV pacing, circumferential strain was significantly increased in late activated posterior segments compared to early activated anterior segments or control (P<0.05). Conversely, during posterior LV pacing, circumferential strain was significantly increased in late activated anterior segments compared to early activated posterior segments or control (P<0.05). Radial strain also showed similar patterns of changes. However, no statistical significance was detected. The enhanced strain was associated with the prolongation of action potential duration in late activated LV segments (2).

Conclusion

In the current study, we demonstrated that pacing induced alterations in myocardial strain patterns in LV segments with significantly increased circumferential strain in the late activated segments. The late activated segments also exhibited prolonged action potential duration, which may serve as the electrophysiologic basis for T-wave memory. The altered strain patterns in late activated segments may represent a potential mechanism for triggering VER.

References

1. W Liu, J Chen, S Ji, JS Allen, PV Bayly, SA Wickline, X Yu. HARP MRI tagging for direct quantification of Lagrangian strains in rat hearts after myocardial infarction. *Magn Res Med* 52:1282-1290, 2004.
2. D Jeyaraj, L Wilson, X Wan, J Zhong, T Said, C Flask, I Deschenes, E Ficker, X Yu; JE Saffitz, DS Rosenbaum. Segmental strain as novel mechanism for ventricular electrical remodeling underlying T-wave memory. *Scientific Sessions, AHA*, 2005

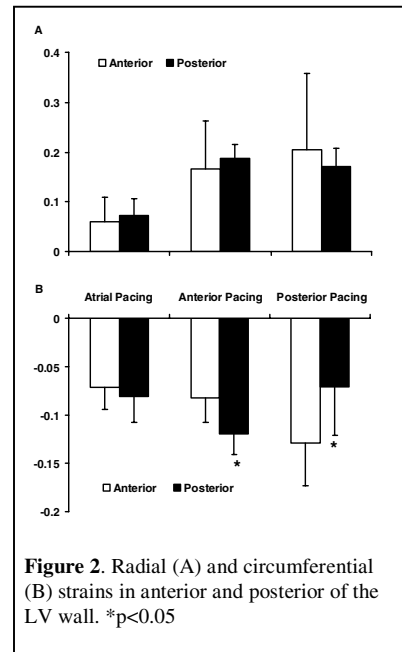


Figure 2. Radial (A) and circumferential (B) strains in anterior and posterior of the LV wall. *p<0.05