

## T2\* Measurement during First-Pass Contrast Enhanced Cardiac Perfusion Imaging

P. Kellman<sup>1</sup>, A. H. Aletras<sup>1</sup>, L-Y. Hsu<sup>1</sup>, E. R. McVeigh<sup>1</sup>, A. E. Arai<sup>1</sup>  
<sup>1</sup>NHLBI/NIH, Bethesda, MD, United States

### Introduction

First-pass contrast enhanced cardiac perfusion imaging will experience T2\* effects at the peak concentrations of contrast agent. Reduction in the signal intensity of the LV blood due to T2\* losses may effect estimates of the arterial input function used for quantitative perfusion measurement. Imaging artifacts may also result from T2\* losses as well as off-resonance due to susceptibility of the bolus. The purpose of this study was to directly measure T2\* in the LV cavity during first pass perfusion imaging and to generate first pass dependent B0 field maps using a custom EPI sequence. Individual images at each TE were reconstructed at reduced spatial resolution and T2\* was estimated by exponential fit to the multi-echo dataset.

### Methods

Imaging was performed on a Siemens Avanto 1.5T scanner using a custom saturation recovery (SR) sequence with GRE-EPI readout. For each echo (echo train length = 4) the same phase encode lines were acquired and low spatial resolution images were off-line reconstructed (using MATLAB) for each TE. T2\* estimates and field maps were calculated from the multi-echo datasets. The frequency readout was 160 samples with bandwidth = 1645 Hz/pixel, TR=5.5 ms, and echo times TE= 1.30, 2.22, 3.14, 4.06 ms. Four slices were acquired sequentially during each RR-interval (ECG triggered) with each slice acquired following a 90° saturation preparation with TD=50 ms prep time. A BIR4 RF SR prep pulse was used [1]. The readout flip angle was 25° for SR prepped images (2 initial frames without SR prep using 5° readout were acquired as proton density weighted reference images). The actual number of phase encodes acquired was 14 resulting in an imaging duration of 77 ms. Parallel imaging using rate R=2 TSENSE [2] was used with 12-array elements to increased the spatial resolution to 160x28 matrix size. Typical FOV was 360x270 mm<sup>2</sup> with corresponding in-plane spatial resolution of 2.3x9.6 mm<sup>2</sup>. Phase reference scans acquired at the start of scan were used in the reconstruction to reduce EPI ghosting.

Contrast studies were performed on 10 normal volunteers with informed consent. In all 10 subjects, 8 mm slices were acquired; in 7 of the 10 volunteers, 4 mm slices were additionally acquired. Short axis views were acquired in all subjects. In 8 subjects, short axis (2 slices) and long axis (2 and 4 chamber views) were acquired so that T2\* could be estimated with the rectangular voxel in different spatial orientations. T2\* was estimated by least squares fit of exponential to the signal intensity of 4 TE images. Field maps were calculated as phase difference between 1<sup>st</sup> and 3<sup>rd</sup> echo images, acquired in the same readout direction. Bolus contribution to off resonance was determined relative to the pre-contrast reference images.

Images were acquired for 40-50 heartbeats beginning approximately 2 seconds prior to administering a single dose bolus (0.1 mmol/kg) of contrast agent (Gadopentetate Dimeglumine, Berlex Magnevist) at 5 ml/s followed by a saline flush (20 ml at 5 ml/s); contrast agent was administered intravenously in the left antecubital vein. Peak concentrations of Gd in the LV were estimated to be 12-15 mMol with corresponding T1 ranging from 15-20 ms.

### Results

The LV blood pool signal intensity at the time of peak contrast enhancement was visibly reduced due to T2\* loss at longer values of TE (Fig. 1). The time intensity curves for LV blood pool ROI (Fig. 2) show that T2\* effects are only significant at high Gd concentrations during the 1<sup>st</sup> pass. The undistorted time intensity curve (Fig. 2 dotted line) estimated for TE=0 is shown for comparison. Measurement of T2\* of the LV blood pool at peak concentration for full dose was 9.1±3.1 ms (mean±SD, N=10) for 8 mm thick SAX slices, 8.8±4.3 ms (mean±SD, N=7) for 4 mm thick SAX slices, and 9.1±2.8 ms (mean±SD, N=8) for 8 mm thickness in LAX slices (4 chamber view), with minimum T2\* ranging from 5.6 to 18 ms.

Field maps (not shown) were highly variable. Off-resonance was noted during peak enhancement and varied significantly within the LV, with variation of approximately 80 Hz in some cases.

### Discussion

There was no significant difference in the measured T2\* for different voxel sizes or orientations. Gradients in the measured field maps were not sufficient to explain intravoxel dephasing. The measured T2\* values are believed to be an intrinsic (i.e., microscopic) property at this level of peak Gd concentration and are, therefore, representative of higher spatial resolution used normally in 1<sup>st</sup> pass imaging. These measurements support the statement [3] that T2\* losses are not significant for measurement of arterial input function (AIF) at short TE. For clinical scans at TE=0.6ms T2\* losses are 5-10% for T2\* in 6-12ms range, and 4-8% at TE=0.5ms (in research mode 40mT/m@200T/m/s). T2\* and off-resonance effects on the point spread function are being analyzed.

### References

- [1] Kim D, et al. MRM. 2005 (Dec);
- [2] Kellman, et al. MRM. 2001; 45(5): 846-52.
- [3] Gatehouse, et al. JMRI. 2004; 20(1):39-45.




Fig 1. Multi-echo short axis images at time of peak LV enhancement

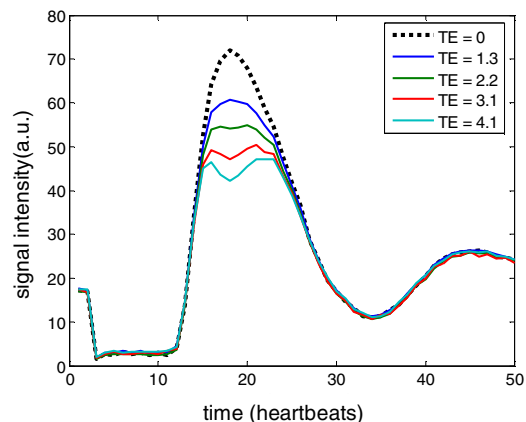


Fig 2. Time intensity curves for LV blood pool ROI for each echo time.