

A Dual-Bolus Imaging Method for the Estimation of Myocardial Distribution Volume

N. Pack^{1,2}, E. V. DiBella^{1,2}, C. J. McGann³

¹UCAIR, Department of Radiology, University of Utah, Salt Lake City, Utah, United States, ²Department of Bioengineering, University of Utah, Salt Lake City, Utah, United States, ³Division of Cardiology, University of Utah, Salt Lake City, Utah, United States

Introduction:

Delayed enhancement imaging is a powerful tool for the visual assessment of infarct in the myocardium. Alternatively, the volume of distribution, V_d , of the contrast agent (CA) Gd-DTPA in the myocardium provides another measure of myocardial tissue necrosis. In dynamic imaging, the magnitude and spatial distribution of V_d may provide additional information to delayed enhancement imaging to better characterize the changes of infarcted tissue in the myocardium in serial studies and may assist clinicians in tracking the progress or impacting the therapies of various disease states. In this study we present a novel dual-bolus imaging method that may provide a means to more accurately quantitate the late kinetics of tissue enhancement and the regional V_d in the myocardium. This method uses a modified two-compartment model with an extended dual-bolus AIF to provide additional information about the delayed kinetics of tissue enhancement.

Methods:

Myocardial perfusion images were acquired with a Siemens Trio 3T scanner (N=3) and a Siemens Avanto 1.5T scanner (N=1) using an ECG-gated, TurboFLASH pulse sequence with saturation recovery magnetization preparation (TI=113ms, TE=1.26ms, flip angle=15, FOV=344x258mm, matrix=192x101, 8mm slice thickness). During imaging, each patient was sequentially given a low-dose (0.01–0.025 mmol/kg) and high-dose (0.09–0.15 mmol/kg) bolus injection of Gd-DTPA at 6cc/s, using a power injector. After each perfusion scan, a non-bolus scan was acquired to determine the late enhancement kinetics of the tissue. Offline, the reconstructed images were manually registered to sub-pixel resolution and regional blood and myocardial tissue regions were selected to obtain dynamic curves for each perfusion series. The dynamic tissue and blood curves for each series were concatenated and the saturated AIF of the high-dose bolus was upsampled for modeling. Precise image acquisition times were obtained from the scanner in order to accurately concatenate the AIF and tissue enhancement curves from each series. This “time-stamped” concatenation process accounts for each patient’s variable heart rate during the scan and allows for accurate timing between the bolus and non-bolus image series. A cubic interpolation scheme was used to concatenate the images series. To account for regional coil sensitivity, the enhancement curves were normalized to the mean pre-contrast myocardial tissue signal. Quantitative perfusion and V_d measurements were derived by deconvolution of the measured AIF curves with the impulse response of a modified two-compartment model [3]. The tissue enhancement curves, C_{tis} , from any multi-bolus CA injection are accurately described by the convolution of the multi-bolus AIF with a single impulse response function derived from the compartmental model (see Eqn. 1 and Figure 1).

$$C_{tis}(t) = AIF * K_1 e^{-k_2 t} \quad (1)$$

Results:

Figure 1 depicts a delayed dual-bolus AIF with the corresponding tissue enhancement curves for a viable and infarcted region of the myocardium in one patient. Figure 2a depicts the delayed enhancement image that corresponds to the curves from Figure 1. The arrow in the septum denotes the region of infarct, while the viable tissue curve was created from a normal region selected in the lateral free wall of the myocardium. Figure 2b depicts a discrete representation of the spatial distribution of K_1 in 32 regions of the myocardium. Note that regions of low flow (dark regions) coincide with the infarcted septal region of Figure 2a. The mean values of V_d and K_1 for viable myocardium are 14.77 ± 2.38 (mL/100g) and 0.83 ± 0.07 (mL/min/g). The region of infarct had a mean V_d of 20.02 ± 1.16 (mL/100g) and a mean K_1 of 0.67 ± 0.15 (mL/min/g).

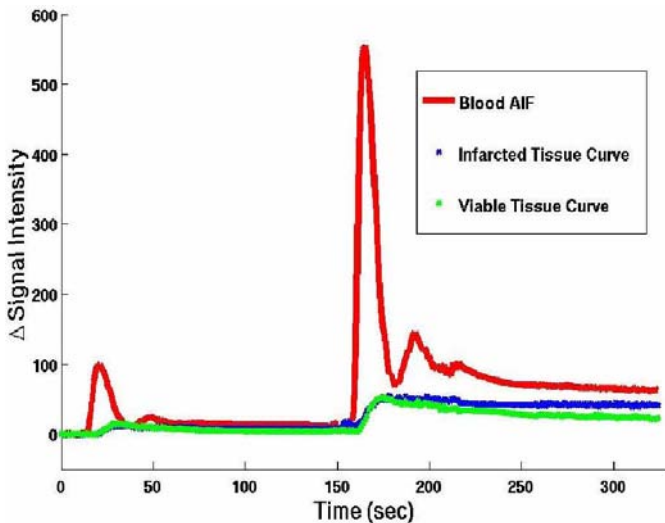


Figure 1

Discussion and Conclusion:

The dual-bolus method presented here uses multiple bolus injections of CA in order to obtain additional information about the first-pass kinetics and delayed kinetics of myocardial tissue enhancement. This is similar to the pre-bolus methods [1,2], in which an upsampled very low-dose bolus injection of CA is used to replace the arterial input function (AIF) of the high-dose bolus injection to then estimate perfusion from a single set of tissue enhancement curves. In our method, we simultaneously analyze multiple concatenated AIF and tissue curves to measure and quantitate V_d from the kinetics of tissue enhancement. The magnitude and spatial distribution of V_d may be used to complement delayed enhancement imaging to better characterize the changes of infarcted tissue in the myocardium in serial studies. Unlike other methods that require nearly 20 minutes to reach steady state tissue enhancement [4], this method requires only a few minutes of acquisition time immediately after each bolus to measure the tissue enhancement curves for estimating V_d . Furthermore, our dual-bolus method readily differentiates between the ventricular blood signal and high signal enhancement in the tissue [5]. Preliminary results demonstrate that this method can be used to differentiate between viable and infarcted regions of the myocardium and provide quantitative metrics of V_d and K_1 .

Acknowledgements: This study was supported by NIH 1RO1 EB000177

References: [1] Kostler H. et al. MRM 2004; 52:296-299; [2] Christian T. et al. Radiology 2004; 232:677-684; [3] Valee J. et al. JMRI 1999; 9:197-203; [4] Klein C. et al. JMRI 2004; 20:588-594; [5] Kellman P. et al. JMRI 2005; 22:605:613.

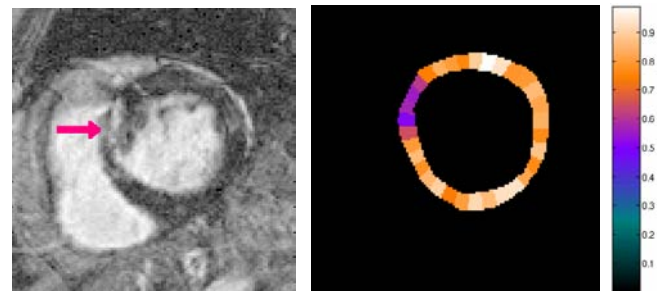


Figure 2a

Figure 2b

Figure 1 depicts a delayed dual-bolus AIF with the corresponding tissue enhancement curves for a viable (green curve) and infarcted (blue curve) region of the myocardium. Figure 2a depicts the delayed enhancement image that corresponds to the curves from Figure 1. The arrow in the septum denotes the region of infarct. Figure 2b depicts a discrete representation of the spatial distribution of K_1 in 32 regions of the myocardium. The dark regions of low flow (K_1) coincide with the infarcted septal region of Figure 2a.