

MR imaging of the female pelvis at 3T: evaluation of image heterogeneity using different dielectric pads

M. Kataoka¹, H. Isoda¹, Y. Maetani¹, Y. Nakamoto¹, T. Koyama¹, S. Umeoka¹, K. Tamai¹, A. Kido¹, T. Saga¹, N. Morisawa¹, K. Togashi¹

¹Diagnostic Imaging and Nuclear Medicine, Kyoto University Graduate School of Medicine, Kyoto, Japan

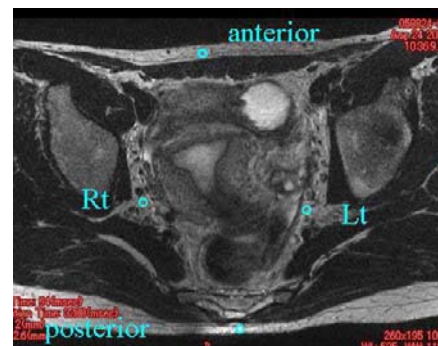
Introduction

Numerous studies in neuroimaging showed that MR imaging at 3T has advantage over that at 1.5T. The gain on SNR, which in turn can be used to improve spatial resolution or temporal resolution is also attractive to the body MR imaging. The application of 3T MRI to the female pelvis is limited (1, 2), but promising result has been reported in obtaining high-resolution image (2), which is unlikely to be achieved at 1.5T. In order to make the most of the advantage of 3T MR imaging, several problems at 3T including B1 inhomogeneity should be considered. A few report suggested the use of dielectric pad made with water doped with MnCl₂ or US gel doped with Gd-DTPA to solve the problem (3-5). However, there is no report comparing both types of pad and also no report on expected improvement in different sequences. This study aimed to evaluate the improvement of signal inhomogeneity at pelvic MR imaging at 3T using two different dielectric pads (pad made of US gel, made of water) on T2WI, T1WI and HASTE.

Material and Methods

Study population and MR scanning protocol: Six healthy females were scanned by 3 T MR scanner (Magnetom Trio, Siemens, Erlangen, Germany) with 8-channel body array coil. MR study was planned to avoid their menstruation. Axial and Sagittal fast spin echo T2-weighted image (T2WI) (TR/TE/thickness/signal average=3200 msec/94 msec/2 mm /3), axial fast spin echo T1-weighted image (T1WI) (700 msec / 11msec/ 3 mm/1) and sagittal HASTE images were used for pelvic imaging. This series of sequences were repeated with the use of US gel pad (doped with Gd-DTPA), water-filled solution bag (doped with MnCl₂), and nothing.

Image analysis: Signal intensity of the fat was used as a marker of signal inhomogeneity for each sequence and the use of dielectric pad. Representative slice was selected close to or including uterine cervix. For axial images, ROI was selected at 1) anterior subcutaneous fat, 2) fat at right pelvis, 3) fat at left pelvis, 4) posterior subcutaneous fat as indicated in the figure. For Sagittal images, ROI was selected at 1) anterior subcutaneous fat, 2) fat close to the uterine cervix, 3) posterior subcutaneous fat. The ratio of minimum signal intensity versus maximum signal intensity among the three or four ROIs were calculated and used as a marker of heterogeneity: high ratio close to 1 means homogenous signal intensity of the image, while low ratio close to 0 means severe inhomogeneity. For statistical analysis, paired-t-test with Bonferroni correction was used to compare signal heterogeneity with the use of RF cushion, water-containing solution bag, and without pads.



Results

Ratio of signal intensity was significantly higher in images between those obtained with the use of US gel-dielectric pad (PAD) and those obtained without any pad on T2WI and T1WI. Images obtained with water-bag pad also showed higher ratio of signal intensity, meaning more homogeneous images, than those obtained without any pad (Axial T2WI and T1WI). There was no significant difference between images obtained with US-gel pad and water-filled solution bag, although US-gel pad tended to show more homogeneous image. There was no significant difference in the ratio of signal intensity in HASTE.

Discussion

This study has demonstrated the effect of dielectric pads in improving signal inhomogeneity in pelvis imaging at 3T. It is suggested that both pads made of US gel or water are useful and there was no significant difference regarding the improvement of homogeneity. Other option of improving signal homogeneity includes the use of coupling coils (6) or the use of multi-channel array coils. Before these promising techniques has become available, the use of dielectric pad is crucial in obtaining excellent MR images of female pelvis, where T2WI is important in its clinical use.

References

1. N. Morakkabati-Spitz et al., Eur Radiol 2005; 15:639-644.
2. N. Morakkabati-Spitz et al., Eur Radiol 2005: E-pub.
3. F. Schick Eur Radiol 2005: 15:946.
4. M. Schmitt et al., ISMRM 12th Meeting (2004); 197.
5. M. Sreenivas et al., ISMRM 13th Meeting (2005); 2745.
6. M. Schmitt et al., ISMRM 13th Meeting (2005); 331.

Graphs showing the ratio of signal intensity among different sequences.

Red line indicate the combination showing significant difference (p<0.05) regarding ratio of signal intensity.

PAD: US gel dielectric pad doped with Gd-DTPA. Water: Water filled solution bag doped with MnCl₂. No: without using any of the dielectric pad

