

Effects of Aging on Hippocampal Subfields and Whole Brain Gray and White Matter Volumes Measured at 4 Tesla

S. G. Mueller¹, L. Stables², A. Du¹, D. Truran¹, N. Cashdollar¹, N. Schuff¹, M. W. Weiner¹

¹Center for Imaging of Neurodegenerative Diseases, VAMC San Francisco, San Francisco, CA, United States, ²Center for Imaging of Neurodegenerative Diseases, VAMC, San Francisco, CA, United States

Background

Memory is one of the most commonly affected cognitive domains in elderly healthy subjects suggesting an involvement of memory related brain structures particularly the hippocampus in the aging process. Findings of neuroimaging studies have been controversial with some showing age related hippocampal volume loss while others did not. One reason for these divergent findings might be that the hippocampus is not a homogenous structure but consists of histologically and functionally different subfields. There is evidence that disease processes, e.g. Alzheimer's disease, affect these subfields differently and this might also be true for aging. Therefore, the aims of this study were: 1. To test if hippocampal subfields can be reliably identified and marked using anatomical landmarks on high resolution MR images. 2. To test if age-specific volume changes of subfields can be detected. 3. To determine the relationship between age-related alterations in hippocampal subfields and whole brain gray and white matter.

Methods

53 healthy and cognitively normal controls spanning an age range from 18-85 years (mean 52.3± 17.8 years, m/f: 30/23) were studied on a Bruker MedSpec 4T system equipped with an eight channel phased-array receive coil. The following sequences were obtained: 1. Volumetric T1-weighted gradient echo MRI (MPRAGE) (TR/TE/TI = 2300/3/950 ms, 7° flip angle, 1.0 x 1.0 x 1 mm³ resolution). 2. High resolution T2 weighted fast spin echo sequence (TR/TE: 3500/19 ms, echo train length 15, 18.6 ms echo spacing, 160° flip angle, 0.4 x 0.5 mm in plane resolution, 2 mm slice thickness, 24 interleaved slices without gap, angulated perpendicular to the long axis of the hippocampus. The MPRAGE was segmented using Expectation-Maximization Segmentation (1). On the high resolution T2 weighted image the entorhinal cortex (ERC), subiculum, CA1, CA2 and CA3/4 & dentate compound on both sides were marked on five consecutive slices using anatomical landmarks (Fig1). Nine subjects were marked twice by two different raters. Intraclass correlation coefficients were calculated to assess the reliability of markings within and between raters. Linear regression analysis was used to test the influence of age and gender on each hippocampal subfield and on total gray and white matter volumes. To test if these volumes change disproportionately across the age range, subjects were grouped into four age groups (group 1: 18-29 years; group 2: 30-49 years; group 3: 50-69 years; group 4: 70 years and above). Differences between age groups were compared using a one-way ANOVA; corrections for multiple comparisons of post hoc analyses were performed with Duncan's test.

Results

The ICC for subfield marking by the two raters indicated generally high consistency within and between raters (ICC>0.75). The volumes of ERC ($r = -0.34$, $p=0.026$), CA1 ($r = -0.51$, $p<0.0001$, cf. Fig 2), total gray matter ($r = -0.73$, $p<0.0001$, cf. Fig 3) and total white matter ($r = -0.37$, $p = 0.009$) were significantly negatively correlated with age ($p = 0.003$, $r = -0.42$). The volumes of ERC ($r = 0.34$, $p = 0.006$) and CA1 ($r = 0.47$, $p = 0.0001$) were significantly correlated to total GM volume. When testing for disproportionate volume differences across the age range, a significant effect for age group was found for CA1 ($F = 6.83$; $df = 3, 49$; $p = 0.0006$; larger in groups 1 and 2 than in 3 and 4) and for total gray matter ($F = 18.8$; $df = 3, 49$; $p < 0.0001$; larger in group 1 than 2, 3, 4 and larger in 2 group than 3 and 4).

Figure 1

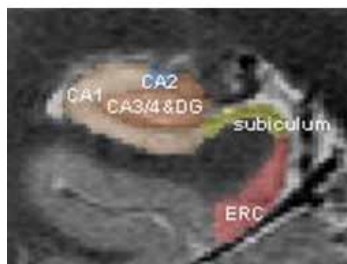


Figure 2

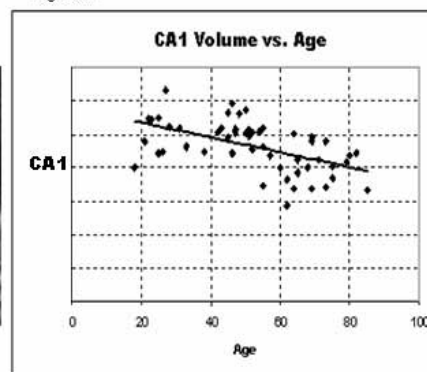
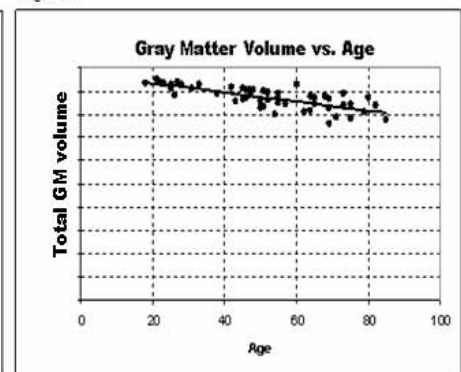


Figure 3



Discussion

We demonstrate that it is possible to reliably depict details of the internal structure of the hippocampal formation on high resolution T2 weighted MRIs at 4Tesla which can be used for marking of hippocampal subfields. Our results indicate that specific regions in the hippocampus, notably CA1 and the ERC are more susceptible to aging than others. Furthermore, volume loss in these regions seems to accelerate after the fifth decade of life, in contrast to GM loss, which seems to start early in life and to progress continuously. These topological variations of age-related alterations in hippocampal subfields and cortex may help to better differentiate between healthy aging and pathological alterations, such as in Alzheimer's disease.

References

1. Van Leemput K et al. IEEE transactions on medical imaging 1999; 18: 897-908