

7T high resolution breast MRI

R. F. Lee¹, L. Moy¹, R. Brown², K. McGorty¹, C. Stefanescu¹, Y. Wang², N. Peck³

¹Radiology, New York University, New York, New York, United States, ²Radiology, Conell University, New York, New York, United States, ³Surgery, New York University, New York, New York, United States

INTRODUCTION Currently, mammography remains the gold standard for breast cancer screening and detection (1). However, radiation risk and decreased sensitivity are seen with dense breasts, limiting its usefulness among higher-risk young women (2). MRI has been evaluated for breast imaging because it relies on the enhancement of cancers after the administration of a contrast agent, and in turn, is unaffected by breast density (3).

At 1.5T, the inadequate sensitivity and specificity of breast MRI prevent it from replacing mammography (4). The quality of breast MRI at 7T, however, should be significantly improved due to the intrinsically high signal-to-noise ratio. We have constructed a 7T breast coil and scanned ten volunteers. Our findings prove that at 7T, high resolution ($0.3 \times 0.3 \times 0.8 \text{ mm}^3$) *in vivo* breast images can be easily obtained, and milk duct and glandular tissue structure can also be identified.

METHOD At 7T, sample loss decreases (loss $\tan \delta$ in Tab. 1), but coil loss increases compared with that of a lower field such as 1.5T or 3T. Thus, a well-made 7T coil has a lower maximum loading factor and needs to include a second conductor such as a shield in order to reduce the radiation loss. The coil for each breast, shown in Fig. 1, is a two-turn solenoid made from a 1.3cm wide copper strip with seventeen 15pF distributed ATC capacitors, three Voltronics trimmers for tuning and matching, and a segmented copper shield that is 1cm away from the coil. The gaps between the segments of the shield are 0.2cm, and they are bridged by 470pF ATC capacitors. When the coil is unloaded, its Q is 349, its impedance is 185Ω , and S11 is -4.7dB at 297.9MHz, as shown in Fig. 2. When the coil is loaded inside the bore with a medium size breast, its Q is 77, its impedance is 50Ω , its S11 is -40dB at 297.2MHz, which is our scanner's central frequency, as shown in Fig. 3.

Because the dimensions of the average breast are small compared to the wavelength of the electromagnetic field at 297.2MHz, the dielectric resonance effect is not as pronounced as it is for the head and body, and in turn, the homogeneous **B1** can be achieved for the volume coil. Since the texture and structure of the breast are continuous, there is no obvious source of severe susceptibility, and the homogenous **B0** can be shimmed.

Tab. 1	breast	fat	
	permittivity	conductivity	$\tan \delta$
1.5T	7.04	0.035	9.92
3.0T	6.22	0.039	5.29
7.0T	5.82	0.045	2.7

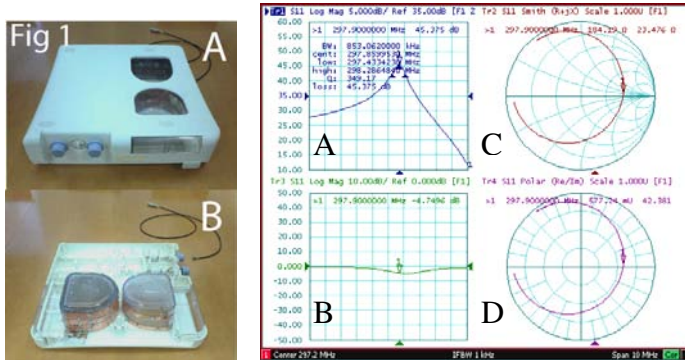


Fig. 2
Unloaded coil
Performance:
A. Impedance
B. S11 amplitude
C. Smith chart
D. Polar expression

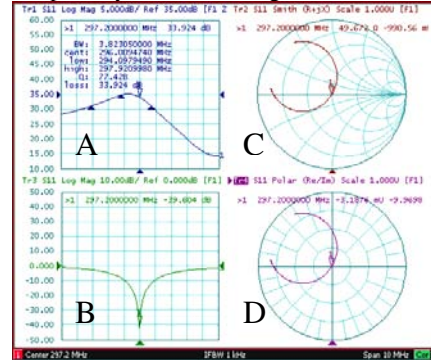
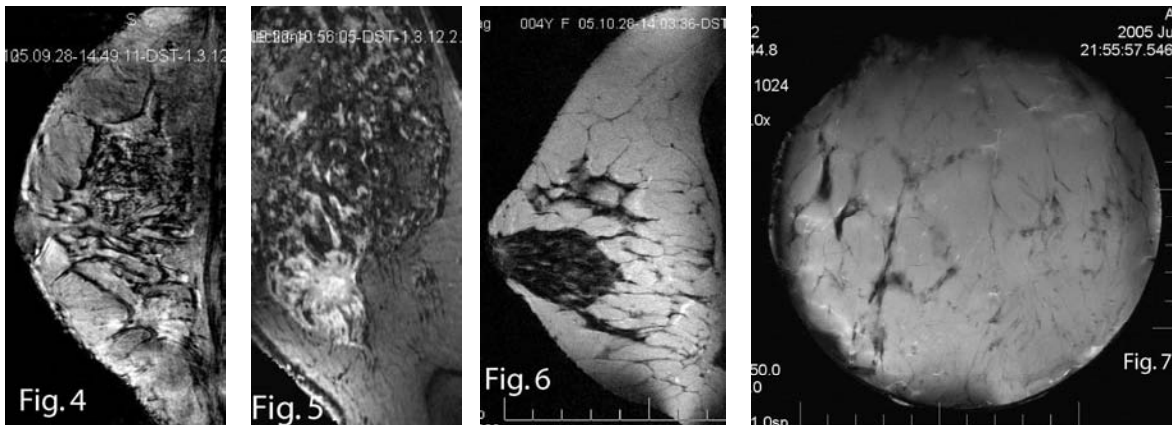


Fig. 3
Loaded coil
Performance:
A. Impedance
B. S11 amplitude
C. Smith chart
D. Polar expression

EXPERIMENTS Using the 7T breast coil, a series of *in vivo* and *ex vivo* experiments were conducted on a Siemens 7T MRI scanner. (1) The T1-weighted images were acquired with 3D FLASH, where TR=11ms, TE=4.2ms, slice thickness=0.8mm, average=1, FOV=160mm, resolution=512x512, slice per slab=144. The single breast can be scanned with a voxel size of $0.3 \times 0.3 \times 0.8 \text{ mm}^3$ in 9min. With such high resolution, the milk duct and glandular tissue were clearly depicted, as seen in Fig. 4, and the tumor structure could be imaged as well (Fig. 5). (2) The T2-weighted images were acquired with a Turbo Spin Echo (TSE) sequence, where TR=4170ms, TE=72ms, echo train=7, slice thickness=1mm, resolution 464x512, FOV 17.7x16.0cm, See Fig. 6. (3) The *ex vivo* sample is free from any subtle motion and perfusion effect, allowing us to find out how much resolution can be achieved in an ideal case. Fig 7 is a fresh breast tissue excised in eight hours. We used TSE, TR=8110ms, TE=21ms, ET=7, FOV 18cm, slice thickness=1mm, resolution 1024x1024. The voxel size is $0.176 \times 0.176 \times 1 \text{ mm}^3$.

CONCLUSIONS Our experiments suggest that 7T breast MRI is a promising modality that may be used to generate very high resolution breast images regardless of the size, texture, or age of the breasts. It can significantly improve the sensitivity/specificity of screening and diagnostic tools.



REFERENCES:
 (1) Ikeda DM, et al, JMRI 12:975, 2000.
 (2) Smith JA, et al, Annals of Oncology 15 (Supp 1) :i18, 2004.
 (3) Morris EA, Seminars in Ultrasound, CT, and MRI 24(1):45, 2003.
 (4) Bluemke D, et al, JAMA 292(22):2735.