

# 1H-MR Spectroscopy of the Prostate at 3.0 T with a phase-array surface coil

F. Traeber<sup>1</sup>, N. Morakkabati-Spitz<sup>1</sup>, U. Jaeger<sup>1</sup>, M. P. Wattjes<sup>1</sup>, P. Bastian<sup>2</sup>, A. Schmitz<sup>1</sup>, J. Gieseke<sup>3</sup>, O. Guer<sup>1</sup>, W. Block<sup>1</sup>, R. Bloemer<sup>1</sup>, H. H. Schild<sup>1</sup>

<sup>1</sup>Department of Radiology, University of Bonn, Bonn, Germany, <sup>2</sup>Department of Urology, University of Bonn, Bonn, Germany, <sup>3</sup>Philips Medical Systems, Best, Netherlands

**Introduction:** Proton MR spectroscopy (<sup>1</sup>H-MRS) of the prostate has been established recently as an important tool in cancer diagnosis and treatment monitoring. The characteristic metabolite pattern observed in malignant prostate disease is an elevation of choline and a reduction of citrate signal. However, the high spatial resolution needed for detection of small lesions or peripheral zone infiltration requires further MRS signal increase. At 1.5 T this is only possible by application of endorectal coils. Purpose of our study was to optimize the acquisition parameters of single-voxel and of spectroscopic imaging sequences at 3.0 T and to test the feasibility of highfield MRS of the prostate without use of endorectal coils.

**Methods:** Water-suppressed single-voxel <sup>1</sup>H-MRS (SVS) and 2D spectroscopic imaging (2D-SI) of the prostate gland were performed with PRESS localization on a clinical 3.0 T whole-body MR system (Intera Achieva 3.0 T, Philips Medical Systems). A 6-element phase-array SENSE surface coil was used for MRI and MRS of the pelvis. Measurements in a citrate phantom preceded the in-vivo study to optimize TE at 3.0 T for in-phase detection of the strongly coupled, non-equivalent citrate CH<sub>2</sub> protons at 2.6 ppm. Applying a TR/TE of 1800/132 ms, 38 patients (mean age 66 ± 7 y) with clinical suspicion (increased PSA values) of prostate cancer were investigated before biopsy, and choline/citrate metabolite ratios as well as water T2 values (from unsuppressed T2 relaxometry) were determined in comparison to the results from 10 healthy volunteers. While SVS (volume size 5-11 ml) was acquired with 160 signal averages, 2D-SI was performed with a 16<sup>2</sup> matrix over a FOV of 16 cm and with a slice thickness of 1.5 cm (voxel size 1.5 ml). Postprocessing was done by time-domain analysis using the MRUI software package [1,2].

**Results:** At 3.0 T, the citrate signal (Cit) revealed a quadruplet structure with 8 Hz spacing between the inner components and 16 Hz distance (= J) to the outer lines, and with optimum in-phase detection at a TE of 132 ms. As the in-vivo line widths of the methyl signals of creatine (Cr), polyamines (PA), and choline (Cho) sometimes prevented separate quantification of all individual components, the total intensity t(ChoCr) of the peaks at 3.0-3.2 ppm and the ratio t(ChoCr)/Cit were also calculated in the patients and in the controls. This ratio was significantly higher in 12 patients with histologically confirmed prostate cancer compared to healthy controls (Table 1). Cho/Cit was also increased in the cases with proven malignancy. However, this difference was not significant due to the large variation within the tumor group. In 14 patients with benign prostate disease, the mean values for the metabolite ratios well matched those of the controls. Using a cut-off value of 0.75 for t(ChoCr)/Cit, 8/12 cases of prostate cancer and 12/14 benign cases were diagnosed correctly by MRS at 3.0 T (67% sensitivity, 86% specificity). Water T2 of prostate tissue obtained from a bi-exponential fit was significantly prolonged in cases of malignancy. Although a similar T2 prolongation was observed in prostate hyperplasia, discrimination from malignant disease was possible due to higher percentage of the free water (long-T2) component in benign cases.

**Discussion:** In spite of the reduced rf penetration in body applications at 3.0 T, the signal gain at higher field strengths allows <sup>1</sup>H-MRS of the prostate with sufficient SNR using phase-array surface coils. The results of our study indicate, that prostate MRS at 3.0 T without application of endorectal coils is feasible and yields reliable diagnostic findings. Especially in cases with reduced or missing MRI delineation of the peripheral zone, MRS may provide additional information. Further improvement in the detection of small lesions and discrete infiltration, however, demands 2D- or 3D-SI acquisition with voxel sizes < 1 ml, which may require signal averaging and correspondingly longer measurement duration.

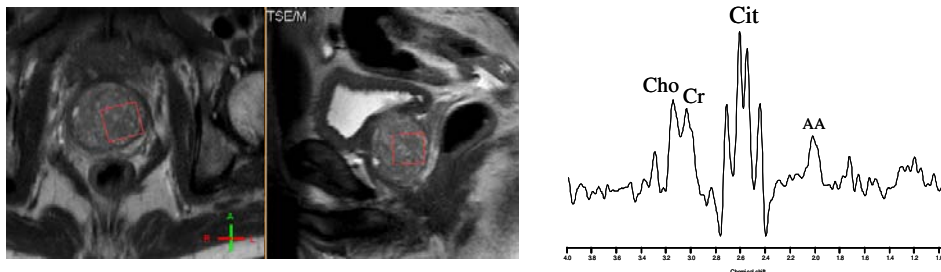


Fig. 1 : Patient with benign prostate hyperplasia, single-voxel spectrum from 6.5 ml VOI, TR/TE 1800/132 ms

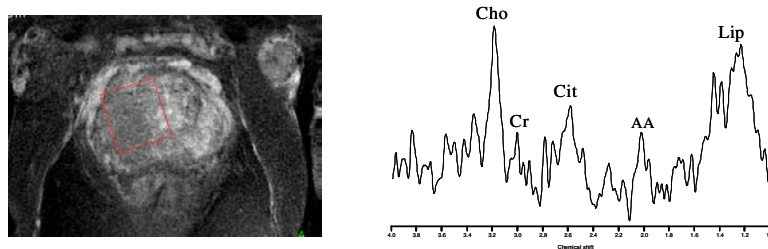


Fig. 3 : Patient with prostate cancer, single-voxel spectrum (VOI 11 ml), Cho/Cit = 1.2

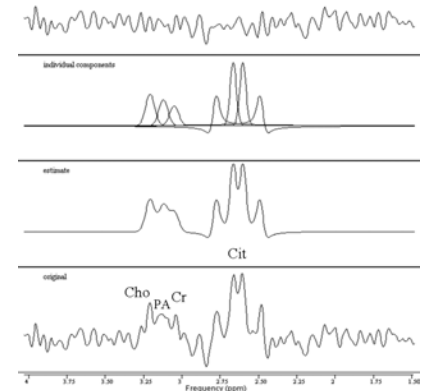


Fig. 2 : Spectrum from 2D-SI data set, 1.5 ml voxel selected in healthy peripheral zone tissue, resulting display from MRUI fitting of 7 peaks (upper row: measured – recalculated spectrum)

**Table 1 :** Metabolic ratios and results of bi-exponential T2 relaxometry from 26 biopsy-proven cases, compared to values from healthy controls (\* p < 0.05 vs. controls, \*\* p < 0.01 vs. cancer)

histology	n	t(ChoCr)/Cit	Cho/Cit	T2 (water) [ms]	% solid (T2 <sub>short</sub> )
cancer	12	0.85 ± 0.27 *	0.45 ± 0.29	61.7 ± 7.1 *	90 ± 6
benign disease	14	0.66 ± 0.20	0.30 ± 0.11	59.0 ± 5.1	81 ± 9 **
controls	8	0.67 ± 0.07	0.26 ± 0.06	54.9 ± 4.5	88 ± 5

## References

1. Vanhamme L, van den Boogaart A, van Huffel S, *J. Magn. Reson.* 129: 35, 1997
2. Naressi A, Couturier C, Devos JM et al., *MAGMA* 12: 141, 2001