

# Daily Priming Stimulation of the Motor Cortex Reduces Hemodynamics

C. B. Glielmi<sup>1</sup>, A. J. Butler<sup>2</sup>, D. M. Niyazov<sup>1</sup>, W. G. Darling<sup>3</sup>, C. M. Epstein<sup>4</sup>, J. L. Alberts<sup>5</sup>, X. P. Hu<sup>1</sup>

<sup>1</sup>Department of Biomedical Engineering, Emory University/GA Tech, Atlanta, GA, United States, <sup>2</sup>Department of Rehabilitation Medicine, Emory University School of Medicine, Atlanta, GA, United States, <sup>3</sup>Department of Exercise Science, University of Iowa, Iowa City, IA, United States, <sup>4</sup>Department of Neurology, Emory University School of Medicine, Atlanta, GA, United States, <sup>5</sup>Department of Biomedical Engineering and Center for Neurological Restoration, Cleveland Clinic Foundation Lerner Research Institute, Cleveland, OH, United States

## Introduction

Repetitive transcranial magnetic stimulation (rTMS) at low-frequency (1 Hz) can lead to inhibition of local cortical excitability resulting in behavioral change that outlasts the stimulation [1]. The lasting inhibitory effect on neurons as a result of rTMS could potentially be utilized in treatment intervention for various neurological disorders [2]. Past work has demonstrated that priming stimulation at a higher frequency (6 Hz) before low-frequency stimulation can enhance cortical inhibition [3]. While immediate effects of rTMS have been extensively studied, there is little evidence on the long-lasting effects of low-frequency rTMS. This study examines the effect of 1 Hz rTMS, both with and without 6 Hz priming, on 5 consecutive days and long-term follow-up to elucidate the effect of rTMS on underlying neural activity using BOLD fMRI. Our goal is to better understand the mechanism of action of rTMS in the healthy human brain as a precursor to potential treatment of a variety of neuropsychiatric disorders.

## Methods

### Subjects and rTMS

We conducted a double-blind study of real versus sham rTMS in five right-handed healthy volunteers (2 real with priming, 2 real without priming, 1 sham). TMS was performed using MAGSTIM Standard Rapid Stimulation centered over the optimal scalp site to elicit response in the right first dorsal interosseous (FDI) muscle. The intersection of the coil was oriented perpendicular to the assumed central sulcus at a 45° angle away from the midline, inducing a tissue current in the posterior-to-anterior direction. Prior to each rTMS session, the site of motor stimulation was defined as the location where the motor threshold was lowest while evoking the largest response [4]. These positions were confirmed in all subjects by an image-guided frameless stereotaxy system (Brainsight, Rogue Research, Montreal, Canada) to localize the sites of TMS of the hand motor area. Resting motor threshold (RMT) was defined as the minimum TMS intensity required to elicit at least 5 out of 10 motor evoked potentials (MEP) when applied over the right hand motor area of the left hemisphere at the frequency of 1 Hz [5]. Following the establishment of RMT, we applied 10 minutes of 6 Hz priming rTMS at 90% RMT (216,000 pulses) followed by 30 minutes of 1 Hz rTMS at 95% RMT (1,800 pulses) for the two subjects receiving primed stimulation. We applied only the 30 minutes of 1 Hz rTMS for the two subjects receiving rTMS without priming. Motor performance was assessed immediately before and after 6 Hz, where applicable, and 1 Hz rTMS by measuring maximum pinch force with a precision transducer. TMS was performed for five consecutive days and motor performance was assessed at baseline, each successive day and the tenth day after the initiation of rTMS.

### Image Acquisition

Prior to rTMS application, we acquired baseline BOLD functional scans on a 3T Siemens Trio scanner. A single-shot gradient-echo EPI sequence was used to acquire T2\*-weighted images over 28 oblique axial slices with TR/TE of 2000/35 ms, matrix of 64x64, FOV of 21cm, slice thickness of 4mm with no gap and acquisition of 135 volumes. Images were acquired during a block design (30 seconds of rest followed by 30 seconds of right index finger abduction) consisting of 5 rest periods and 4 task periods per 4.5 minute scan. Identical image acquisition protocol was repeated immediately following each of the five days of rTMS and on the tenth day after the start of rTMS. BOLD effects were quantified by activated voxel counts, as determined by a general linear model (SPM2) and a mask for left brodmann area 4 [6].

## Results and Discussion

BOLD activation was corrected for multiple comparisons using a false discovery rate (FDR) threshold of  $p < .05$ . Although inter-subject BOLD activation showed

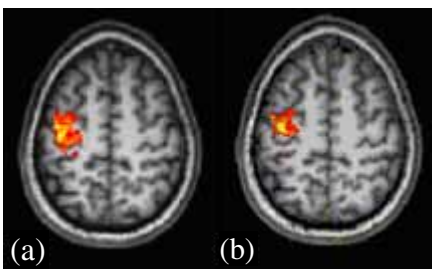


Fig. 3: Active counts in (a) baseline scan and (b) first scan after day 5 rTMS with 6 Hz priming

variability for the sham stimulus to the lack of more subjects in this group. Figure 3 illustrates typical results of decreased voxel counts in the precentral gyrus, or primary motor area, of rTMS subjects in day 5 scans relative to baseline levels.

## Conclusion

The results indicate that low-frequency (1 Hz) rTMS with or without a 6-Hz primer can reduce local hemodynamics. Specifically, contralateral M1 rTMS decreases BOLD response over a 5-day period compared to sham. Further research with more subjects may demonstrate the influence of priming, but our current study combines primed and unprimed rTMS to demonstrate decreased BOLD response for all subjects receiving rTMS.

## Acknowledgements

This work was supported in part by the NIH RO1 EB002009, NS 40984 and Atlanta VA Rehabilitation Research and Development Center of Excellence.

## References

- [1] Romero JR, Ansel D, Sparin R, Gangitan M, Pascual-Leon A. *Clin Neurophysiol* 2002;112(1):101-7.
- [2] Khedr EM, Ahmed MA, Fathy N, Rothwell JC. *Neurology* 2005;65(3):466-8.
- [3] Iyers M, Schleper N, Wassermann E. *J Neuroscience* 2003; 23(34):10867-72.
- [4] Curra, A, Modugno N, Inghilleri M, Manfredi M, Hallett M, Berardelli A. *J Rehab Med* 2003;35(3):41 Suppl:20-6.
- [5] Epstein CM, Schwartzberg DG, Davey KR, Sudderth DB. *Neurology* 1990;40:666-670.
- [6] Maldjian, JA, Laurienti, PJ, Burdette, JB, Kraft RA. *NeuroImage*. 19(3):1233-1239.

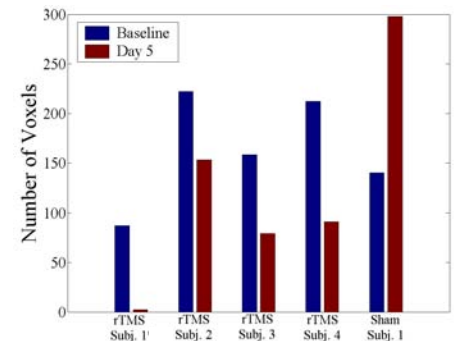


Fig. 1: BOLD voxel counts in contralateral M1 region for baseline and day 5 scans. Subjects 1 and 2 received unprimed rTMS; subjects 3 and 4 received primed rTMS.

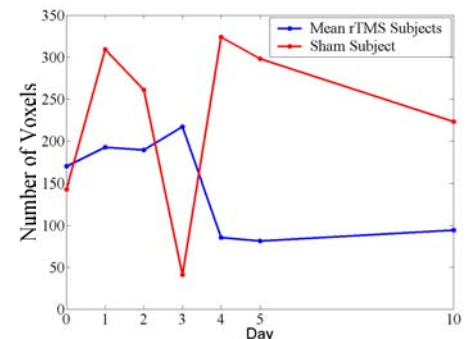


Fig. 2: BOLD voxel counts in contralateral M1 region for each day (primed and unprimed rTMS subjects combined)