

Long T₂ Imaging: Evidence of a New Water Reservoir in Phenylketonuria

C. Laule¹, S. A. Tahir², S. M. Sirrs³, E. E. Brief⁴, C. Bishop⁵, D. K. Li¹, A. L. MacKay^{1,2}

¹Radiology, University of British Columbia, Vancouver, BC, Canada, ²Physics & Astronomy, University of British Columbia, Vancouver, BC, Canada, ³Medicine, University of British Columbia, Vancouver, BC, Canada, ⁴Physics, Simon Fraser University, Burnaby, BC, Canada, ⁵Psychology, University of British Columbia, Vancouver, BC, Canada

Introduction

Phenylketonuria (PKU) is an inborn error of phenylalanine (PHE) metabolism that causes severe mental retardation in most affected individuals who are not treated with a diet restricted in PHE. White matter abnormalities, which are typically symmetric and concentrated in periventricular regions (1), are frequently seen on conventional magnetic resonance imaging (MRI) but do not correlate with clinical status of the patient (2). Magnetic resonance T₂ relaxation measurements in white matter have the potential to provide more specific information about the progressive brain damage that may occur in PKU. Previous T₂ relaxation work in multiple sclerosis has shown abnormalities in brain water content and myelin water fraction (MWF) for both normal appearing white matter (NAWM) and lesions (3) and evaluation of changes in NAWM has been shown to be a sensitive indicator of disease activity (4). To better define the intermediate T₂ components, important for the characterization of abnormal white matter, the total acquisition time of the multi-echo T₂ relaxation sequence was lengthened from 320ms to 1.120s. By extending the length of the decay curve, T₂ relaxation measurements have the potential to more clearly distinguish between different types of pathology in lesions and NAWM. The purpose of this study was to describe what specific T₂ related changes occur in the brains of subjects with PKU.

Methods

Subject Information: 15 patients with PKU and 15 age and gender matched controls underwent MR examinations. All subjects with PKU had been prescribed a low PHE diet from birth and had been maintained on the diet for at least two years prior to the study, although compliance with this diet was highly variable.

MR Experiments: MR experiments were conducted on a 1.5T GE Echo Speed scanner operating at the 5.7 software level. Localizers, axial proton density (PD) and T₂ images (TR 2500 ms, TE 30/80 ms) were followed by a 48 echo modified multi-echo sequence with variable TR, consisting of a 90° slice selective pulse followed by 48 rectangular composite 180° pulses flanked by slice-selective crusher gradient pulses for elimination of stimulated echoes (5). For the multi-echo T₂ relaxation measurement, a single axial slice through the base of the genu and splenium of the corpus callosum was acquired (TR 2120-3800ms depending on the k-space location, TE first 32 echoes @ 10ms, last 16 echoes @ 50ms, 5 mm thick, 128×128, 4 averages).

Data Analysis: Regions of interest (ROIs) were outlined in 5 white matter areas (minor forceps, major forceps, genu, splenium and posterior internal capsules) and classified as either NAWM or diffuse white matter (DiffWM, white matter regions showing hyperintense signal in T₂ weighted images) for subjects with PKU or normal white matter (NWM) for controls. T₂ relaxation decay curves were decomposed into an unspecified number of exponentials using a non-negative least squares algorithm and results were displayed as a T₂ distribution, a plot of component amplitude as a function of T₂ (6). Relative water content (RWC) was calculated as the ratio of the signal (extrapolated to TE=0 ms) from the chosen region of interest to that of an internal grey matter standard (putamen). The MWF was defined as the fraction of the T₂ signal below 50ms relative to the total signal in the T₂ distribution. Similar to the MWF, a "Long-T₂" component fraction was calculated by integrating the T₂ signal between 200 and 800 ms and dividing it by the total signal in the T₂ distribution. MWF and Long-T₂ maps were created for each subject by calculating the fraction of each component for every pixel in the image. Statistical analysis was carried out using a two-tailed Student's t test with a p value of <0.05 considered significant. All errors are expressed as standard deviations.

Results

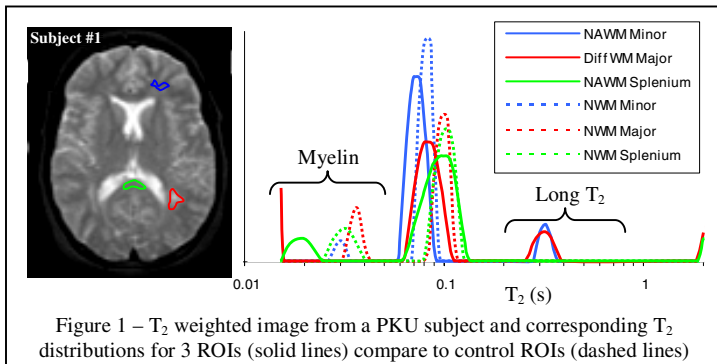


Figure 1 – T₂ weighted image from a PKU subject and corresponding T₂ distributions for 3 ROIs (solid lines) compare to control ROIs (dashed lines)




Figure 2 – Long-T₂ maps from 3 PKU subjects and 3 controls.

Figure 1 shows a T₂ weighted image from a PKU subject with corresponding T₂ distributions for several ROIs compared with a control. Note the T₂ peak at ~300 ms in both the major forceps DiffWM and minor forceps NAWM T₂ distributions shown in Figure 1. This peak contained on average of 9% of the water in the region of interest (7.8(1.8)% and 10.5(2.2)% for DiffWM in the minor and major forceps respectively) and was clearly distinguishable from the main T₂ peak at ~80-90 ms and from the CSF peak (>2 s). This new peak had a T₂ time between 200 and 800 ms and was identified in white matter of 12 of the 15 PKU subjects. The three PKU subjects without this peak had no identifiable white matter lesions in the slice from which the data were acquired. Figure 2 shows Long-T₂ maps from 3 PKU subjects and 3 controls. NAWM is not normal in PKU subjects but exists in two forms: a. Areas which look normal on PD, T₂ and Long-T₂ map images b. Areas which look normal on PD and T₂ images but are hyperintense on Long-T₂ maps. Both forms of NAWM show increased RWC (average 2.9%, range 1.9-3.9%, p<0.001) and reduced MWF (average -14%, range 0.6 to -43.7%, p<0.001) relative to NWM and these changes parallel those seen in DiffWM lesions where RWC was increased on average by 2.6% and MWF was decreased on average by -54.0%. Of interest, the MWF of NAWM was 35% lower than NAWM that was hyperintense on the Long-T₂ map. Figure 2 shows Long-T₂ maps from 3 PKU subjects with corresponding T₂-weighted images and one control Long-T₂ map.

Conclusions

A new water reservoir with a markedly prolonged T₂ peak was identified in NAWM and DiffWM lesions in subjects with PKU. In our study, this new reservoir accounted for approximately 9% of the total water content of the DiffWM. RWC in DiffWM, however, was only ~2.6% higher than NWM in the major and minor forceps. Thus, the redistribution of water into this reservoir exceeds the magnitude of the increase in water content. The nature of the water in this reservoir is not known, but its T₂ peak is separate from that of CSF. Blood also has a prolonged T₂ peak but the literature suggests that there is no difference in cerebral blood flow between subjects with PKU and control subjects (7) so our new reservoir cannot be attributed to blood. We have used our novel MR imaging technique to show consistent increases in RWC and decreases in MWF in subjects with PKU relative to controls. We have also shown that white matter in subjects with PKU which appears normal on conventional MR imaging is not normal, but demonstrates changes in RWC and MWF which parallel those found in obviously diseased white matter structures.

Acknowledgements

The authors wish to thank all PKU and control subjects, and the MR technologists at UBC Hospital. This work was funded by a Vancouver Hospital interdisciplinary grant.

1. Bick U, Ullrich K, Stober U et al. Eur J Pediatr. 1993;152:1012-1020.
2. Dyer CA. Eur J Pediatr (2000) 159 [Sup 2]: S107-108
3. Laule C, Vavasour IM, Moore GRW et al. J Neurol. 2004;251:284-293.
4. Sarchielli P, Prescittuti O, Pelliccioli GP et al. Brain. 1999;122:513-521.
5. Laule C, Whittall KP, and MacKay AL. ISMRM, Glasgow, 2001, p 896.
6. Whittall KP et al. MRM 1997;37(1):34-43.
- Proc Int Soc Mag Reson Med. 14, 2006, 260
7. Huisman TA, van den Brink WA, van der Knaap M, et al. Cerebral Pediatr Res. 1996;40(1):21-29