

Correlating DTI fiber clusters with white matter anatomy

S. Zhang¹, S. Correia², D. F. Tate^{3,4}, D. H. Laidlaw¹

¹Department of Computer Science, Brown University, Providence, RI, United States, ²Department of Psychiatry and Human Behavior, Brown Medical School, Providence, RI, United States, ³Department of Psychiatry and Human Behavior, Centers for Behavioral and Preventive Medicine, Brown Medical School, Providence, RI, United States, ⁴Department of Medicine, Center for AIDS Research, Brown Medical School, Providence, RI, United States

Introduction – We evaluated automated tractography clustering results via expert characterization of white-matter features present in the clustering results, in the tractography results, and in the normal brain. The results show that automated clustering algorithms can identify fiber clusters that correlate with known white matter anatomy and that preserve most features in tractography results. Improvements in data acquisition, tractography, and clustering algorithms have the potential to improve the results.

DTI tractography methods trace sufficiently large coherent neural pathways based on diffusion characteristics in cerebral white matter [1]. These pathways can be grouped into spatially-related bundles that appear to represent underlying white matter anatomy. These DTI fiber bundles have the potential to improve our understanding of white matter anatomy by identifying white matter tracts of interest (TOI) for studying the functional, behavioral, and cognitive impact of white matter disease, injury or development. However, to realize these potentials, the clustering results must be consistent with the underlying white matter anatomy. We conducted an initial assessment of the anatomical accuracy of an automated DTI fiber clustering algorithm.

Methods –A Siemens Symphony 1.5T scanner was used for imaging. Four normal volunteers were imaged. For each, three slice packets of DWIs were acquired sagittally and interleaved to acquire a data volume of 128×128×90 with a voxel size of 1.7×1.7×1.7 mm. The Siemens MDDW protocol was used, with three b values (0, 500, 1000) in 12 directions. Diffusion tensor images were calculated.

Streamtubes models were generated by uniformly seeding in the data volume with a high seeding density of 1/0.85mm³ and jittering in order to cover the entire data volume without aliasing artifacts. Streamtubes were then culled, in order to remove those that were too similar to others (distance threshold = 0.85mm, minimum distance threshold = 0.475mm) [2]. The streamtubes for each subject were clustered using minimum distance clustering [3] with a distance threshold of 3.0mm. Clusters identified by this algorithm are randomly color coded as in the figure. Only clusters with more than 10 streamtubes were retained. A FishTank immersive stereo display was used to examine the models [4].

Two expert raters (neuropsychologists with considerable experience in white matter anatomy and imaging) rated the resulting models in two experiments. In the first experiment, the raters *a priori* selected 11 prominent white matter pathways for bilateral identification in the streamtube models. They identified the pathways using the 3D stereo FishTank environment and rated their confidence: ‘v’ indicated ‘very likely located’, ‘l’ indicated ‘likely located’, ‘p’ indicated ‘possibly located’, and ‘u’ indicated ‘unlocated’. In the second experiment, the raters were asked to repeat the process using each of the four unclustered sets of streamtubes.

Results and Discussion –Results are shown in Table 1. Each row represents one white-matter feature. Each rating pair within a row shows the ratings for that feature in both hemispheres of the brain. A comparison across the four subjects shows that long, thick, coherent fiber bundles like the uncinate fasciculus, cingulum bundles, and superior and middle cerebellar peduncles are well identified by the clustering algorithm. On the other hand, shorter, thinner fiber bundles like the anterior commissure are almost completely missing from the models. This is likely due to the small cross section of the fiber bundles and the limited resolution of the images. Between the extremes, some tracts, like the frontal forceps and the corticospinal tract, are missing or rated low in one subjects, suggesting either an imaging artifact or an anatomical difference for that particular subject. Some tracts, such as the superior longitudinal fasciculus, inferior longitudinal fasciculus, arcuate fasciculus and inferior cerebellar peduncle, were rated inconsistently in most of the subjects. It is important to note that the raters were also suspicious of some clusters not having a true anatomic correlate. A comparison of the clustered and unclustered models of S1 shows that raters are able to identify these tracts better in the unclustered model.

This last result suggests that automated clustering achieves a degree of visual clarity and abstraction in the models, though it does remove some anatomically-relevant information that prevents confident identification of all features. Imaging artifacts, changes in fiber density, the presence of two or more crossing fiber bundles, and partial volume with gray matter and cerebral-spinal fluid can all degrade fiber bundle coherence and prevent the streamtubes from forming large and meaningful clusters. The unclustered model retains all these streamtubes and the raters are able to group them using prior knowledge. Regularizing the diffusion tensor field or probabilistic fiber tracking might generate more coherent pathways and larger clusters. On the other hand, an algorithm aimed at generating more coherent fibers might increase the frequency of spurious connections. Thus, future research in tractography and clustering must find a balance between these seemingly conflicting goals.

Conclusions – We identified a set of white matter fiber tracts and rated their presence in streamtube clustering results for four subjects. We found that, 1) a group of long, thick and coherent fiber tracts are well identified by the clustering algorithm; 2) there are some short, thin fiber tracts that are missing in the fiber tracking and clustering results; 3) some fiber tracts are missing in the clustering results but are still identified in the unclustered model probably due to broken streamtubes, degraded streamtubes, or the cluster size limit. The missing and inconsistent fiber tracts indicate areas for improvement in imaging, data fitting, tractography and clustering.

Acknowledgements - Support from NSF CCR-0086065, NIH EB004155 and the Brain Science Program at Brown.

References – [1] Basser et al. 2000 MRM [2] Zhang et al. 2003 IEEE TVCG [3] Zhang et al. 2005 ISMRM [4] Demiralp et al. 2006 IEEE TVCG

| White matter fiber tract | S1 | S2 | S3 | S4 | S1 unclustered |
|--|-----|-----|-----|-----|----------------|
| frontal forceps (ff) | p | v | v | v | l |
| superior longitudinal fasciculus (slf) | p,u | v,p | v,u | p,l | v,v |
| inferior longitudinal fasciculus (ilf) | u,l | l,l | l,u | l,l | l,l |
| arcuate fasciculus (af) | u,u | v,v | v,u | p,l | l,v |
| uncinate fasciculus (uf) | v,v | v,v | v,v | v,v | v,v |
| anterior commissure (ac) | u,u | p,p | u,u | u,u | u,u |
| cingulum bundle (cb) | v,v | v,v | v,v | v,v | v,v |
| superior cerebellar peduncle (scp) | l,l | v,v | v,v | v,v | l,l |
| middle cerebellar peduncle (mcp) | v,v | v,v | v,v | v,v | v,v |
| Inferior cerebellar peduncle (icp) | p,p | p,u | u,u | l,u | p,p |
| cortico-spinal tract (cst) | v,v | l,u | v,v | v,v | v,v |

Table 1. Rating of presence of 11 white matter features in the clustering models of four subjects. S1-S4 represent clustering results; “S1 unclustered” represents raw tractography results. The ratings are: ‘v’ indicating ‘very likely located’, ‘l’ indicating ‘likely located’, ‘p’ indicating ‘possibly located’, and ‘u’ indicating ‘unlocated’. A rating pair shows the ratings for the same tract in each cerebral hemisphere.

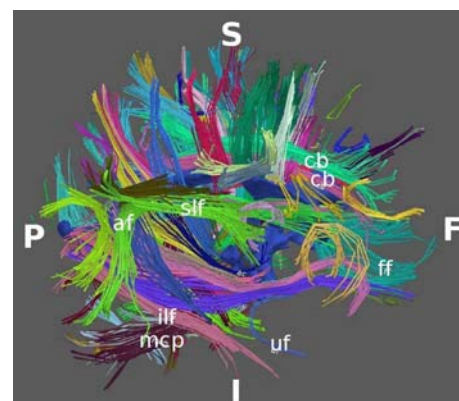


Figure 1. This figure shows labeled streamtube clusters for S2.