

Non-model based correction of respiratory motion using beat-to-beat 3d spiral fat-selective imaging

J. Keegan¹, P. D. Gatehouse¹, G-Z. Yang², D. N. Firmin¹

¹Cardiovascular Magnetic Resonance, Royal Brompton Hospital, London, United Kingdom, ²Department of Computing, Imperial College, London, United Kingdom

Introduction

Respiratory motion remains a major challenge for free-breathing coronary artery imaging techniques. The most recent approach to this problem has been to develop a subject-specific motion model that may be used to correct for the motion occurring within an extended navigator acceptance window (1,2). This technique relies on the acquisition of a calibrating pre-scan in order to determine the motion model (simple linear translation or affine) which is then used to prospectively correct the data acquired in the subsequent scan. Rather than developing a prospective model based on navigator echoes, an alternative approach would be to acquire a low resolution 3d dataset in each cardiac cycle, immediately prior to the acquisition of each data segment contributing to the high resolution image, and use beat-to-beat correlation of this low-resolution data to determine the respiratory motion. This could be corrected for in post-processing(3) and could potentially allow data acquisition throughout the respiratory cycle. It also has the further advantage of not relying on a navigator-based motion model. The aim of this work is to determine the feasibility of this approach for coronary vessel wall imaging.

Methods

This work was carried out on a Siemens Sonata 1.5Tesla scanner. **Data acquisition:** The imaging sequence developed consists of (a) dark-blood preparation (using a selective and non-selective pulse pair), (b) a low resolution 3D spiral acquisition using fat-excitation immediately followed by (c) a high resolution spiral interleaf using water-excitation. A following right hemi-diaphragmatic navigator was also implemented, purely for monitoring purposes. The low resolution dataset (16 x 1.5mm slices (after zero-filling), 3mm x 3mm in-plane resolution) took 150ms to complete and was used as a marker of the heart position for the high resolution interleaf that followed immediately after. The kz phase encoding order for this dataset was reverse centric (ie outer kz to inner kz) so that the centre of kz-space was acquired as close as possible to the high resolution interleaf following. For the high resolution scan, data was acquired over 23 interleaves (one per cardiac cycle). Eight kz phase-encoding steps were acquired for each interleaf resulting in a total acquisition duration of 184 cardiac cycles. The field of view was 205mm resulting in an in-plane resolution of 0.8mm (reconstructed to 0.4mm), with zero-filling in kz allowing the reconstruction of 16 x 1.5mm slices. The high resolution spiral readout duration was 10ms, effectively freezing cardiac motion. **Data processing:** All processing was carried out offline. The low resolution 3D fat images were reconstructed for each cardiac cycle. A single end-expiratory dataset was selected as a reference and a region of interest in the fat surrounding the coronary artery was selected for matching with the datasets acquired in subsequent cardiac cycles. Each low-resolution dataset was cross-correlated with the reference dataset to obtain the x, y and z translations of the selected region from beat to beat. These shifts were used to correct the gridded raw data of the following high resolution spiral interleaf. The feasibility of this approach was assessed by acquiring through-plane spiral coronary artery vessel wall images in three healthy subjects.

Results

Figure 1 shows a single spatially-fixed slice from example low resolution fat-excitation acquisitions in 6 consecutive cardiac cycles, the region of interest used for cross-correlation being defined on the first image (end expiration) and superimposed on those following. The in-plane and through-plane translational motion due to respiratory motion is clearly apparent, despite the low resolution. For this same subject, Figure 2 shows the in-plane and through-plane translation of the selected region of interest throughout the 184 cardiac cycle acquisition plotted against the right hemi-diaphragm position. As expected, the shifts vary approximately linearly with navigator position but there is considerable scatter. Coronary vessel wall images following beat-to-beat correction of respiratory motion were of high quality and are presented in Figure 3 where three contiguous slices from each subject are shown. The range of diaphragm motion over the data acquisition period in these 3 subjects was 25mm, 19mm and 20mm respectively.




Figure 1: A single spatially-fixed slice from 3d low-resolution fat-excitation images acquired in 6 consecutive cardiac cycles. The images were acquired with a surface coil (anterior chest wall at bottom of each image) and the excursion of the diaphragm (in mm) from the end expiratory pause (image (1)) is noted in each. The region of interest for cross-correlation (encompassing the fat surrounding the coronary artery) was defined on image (1).

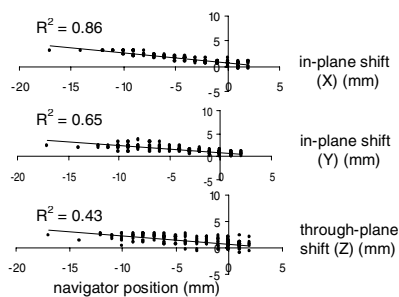


Figure 2: In-plane (X and Y) and through-plane (Z) translations of the region of interest as a function of navigator displacement.

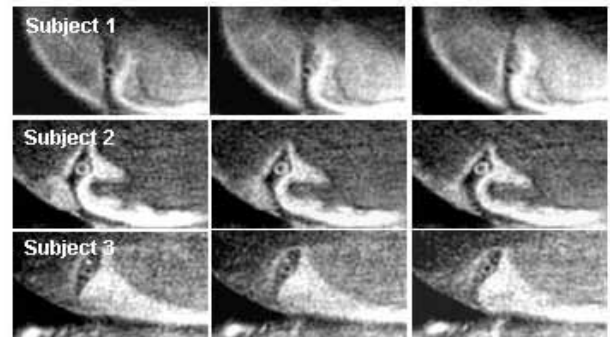


Figure 3: Contiguous slices showing the vessel wall in 3 healthy subjects. (Respiratory efficiency = 100%)

Conclusion

Determination of the translational components of respiratory motion by tracking fat-excitation 3d images from beat to beat appears to be feasible. This has allowed high quality images of the right coronary artery vessel wall to be generated during free-breathing with 100% respiratory efficiency, without the need to determine a respiratory motion model. Future work will focus on improving the image correlation process, allowing more complex motion (such as affine transformations) to be accounted for, and performing a full comparative study against navigator-based techniques.

References: (1) Manke et al., Magn Reson Med 2003, (2) Nehrke et al., Magn Reson Med 2005, (3) Korin et al., Radiology 1990.