

Arcuate Fasciculus Maturation is Impaired Bilaterally in Pediatric Traumatic Brain Injury: A DTI Study at 3.0 T

K. M. Hasan¹, A. Sankar¹, L. Kramer¹, M. R. Prasad², L. Ewing-Cobbs²

¹Diagnostic and Interventional Imaging, University of Texas Medical School, Houston, Texas, United States, ²Pediatrics, University of Texas Medical School, Houston, Texas, United States

Introduction

Closed head traumatic brain injury (TBI) is a major cause of disability amongst children [1]. Following TBI, the largest interhemispheric commissure or corpus callosum (CC) volumes are strongly related to indices of diffuse axonal injury as well as to cognitive measures [2], but few studies have addressed the effect of TBI on intrahemispheric or long association fibers such as the arcuate fasciculus. This structure is an essential compact white matter bundle that connects Broca's and Wernicke's language centers in the left hemisphere. The arcuate fasciculus is known to be lateralized in humans and to mature at a fast rate during this important age [3], thus pediatric trauma is hypothesized to impair the normal development of this important network. Diffusion tensor imaging (DTI) has the potential to help in the localization and quantification of the extent of white matter damage [4-6] and correlation with outcome measures. In this preliminary report, we have used full brain, optimally designed DT-MRI protocol at 3.0 T in combination with conventional MRI sequences to assess the extent of injury post trauma in different white matter structures that are known to mature during childhood and compared the age-maturation trends to healthy pediatric controls. This report focuses on the effect of TBI on the fractional anisotropy (FA) and the transverse diffusivity ($\lambda_t = (\lambda_2 + \lambda_3)/2$) which has been shown in controlled animal studies to be a sensitive marker of the integrity and state of myelin sheaths and their progenitors, the oligodendrocytes [7].

Methods

Subjects: DT-MRI was obtained in 14 TBI cases who sustained moderate to severe TBI at ages 0-15 years; the mean Glasgow Coma Scale score was 7.79 (SD=4.10). The mean age at DT-MRI was 14.3 ± 3.2 years (range 9.6 to 18.9 years); scans were obtained an average of 6.1 ± 2.7 years post injury. The comparison group consisted of 19 cases with a mean age of 10.2 years (range 6.6 to 15.8 years). Parental consent and child assent were obtained. **Conventional and DT MRI Acquisition:** We have acquired entire brain data using a Philips 3.0 T Intera system using a SENSE receive head coil. The MRI protocol included conventional T1w, PD, T2w dual spin echo images (TE1/TE2/TR=10/85/7000 ms) in addition to a matching prescription of diffusion tensor MRI data. The DT-MRI data were acquired using a single shot spin echo diffusion sensitized EPI sequence with the balanced Icosa21 encoding scheme [8], $b=1000 \text{ smm}^{-2}$, TR=6.1 s, TE= 84 ms. To reduce EPI related image artifacts, we used a SENSE acceleration factor R=2. The slice thickness is 3mm with 44 axial slices covering the entire brain, fov=24 cm, and an image matrix of 256x256. The number of b=0 was 8; in addition each encoding was repeated twice and magnitude averaged to enhance the signal-to-noise ratio. The total DTI acquisition time was approximately 7 minutes and resulted in SNR independent ($\text{SNR}_0=60$, $\text{SNR}(\text{DW}) \sim 20$) and reproducible results.

Data Processing and Analysis: Diffusion weighted data were distortion corrected using the mutual information maximization approach [8], the details of the DTI processing are provided elsewhere [8]. The ROI placement procedure was done by trained raters and used anatomical landmarks from the conventional MRI sets (sagittal phase sensitive inversion recovery). The procedure was supervised by a radiologist and used a sophisticated system that fused DTI with conventional MRI (Figure 1) [8].

Results: Figure 1 shows the FA, and transverse diffusivity (λ_t) vs. age variation of the right and left arcuate fasciculus in the healthy pediatric group. Normal maturation is indicated by increase in FA and a decrease in transverse diffusivity with increasing age (Figure 1). Notice that FA increases slowly with age in the right hemisphere of the healthy group; the rate of age-related anisotropy variation is only significant in the left arcuate fasciculus. The transverse diffusivity is more strongly correlated with age than is FA. Figure 2 shows the lack of age variation in the FA and transverse diffusivity measures in the TBI group. Developmental change in the microstructure of the arcuate fasciculus of the TBI group is clearly arrested as indicated by a reduced correlation of both measures with age bilaterally.

Discussion and Conclusions: FA and mean diffusivity ($D_{av} = (2\lambda_t + \lambda_a)/3$) are two popular sensitive indices that capture variation in tissue organization []. Both FA and D_{av} have been shown to lack directional specificity and hence the assessment of both FA and the transverse diffusivity in specific brain regions would allow stronger and more specific determination of the microstructural changes in compact white matter after traumatic brain injury. The lateralized age-related changes measured in these studies on the healthy arcuate fasciculus of pediatric controls are consistent with the results reported by Paus et al. [3] and Schmithorst et al. [10] using MRI volumetry and DTI voxel-based morphometry, respectively. Schmithorst et al. [10] did not present tensor diffusivity related changes and only reported FA values. Our studies also highlight the importance of the transverse diffusivity as a specific surrogate marker of potential impairment of myelination post trauma. Our findings regarding the lack of age-related change in the left arcuate fasciculus after pediatric TBI are consistent with prior reports of post-traumatic diminution of growth of the corpus callosum in children with TBI [2]. The adverse impact of pediatric TBI on the subsequent maturation of white matter likely contributes to the persistent post-traumatic cognitive and behavioral difficulties [6,11]. Information on the microstructural integrity of white matter from indices of transverse diffusivity, coupled with a neuropsychological battery, will be essential in the design of rehabilitation, surgical and therapeutic plans that may enhance remyelination and axonal protection [12].

References [1] Poussaint TY, Moeller KK. Neuroimag Clin N Am. 2002;12(2):271-294, ix.[2] Levin H et al. Neurology 2000; 54:647-653. [3] Paus T et al. Science. 1999;283(5409):1908-1911.[4] Neil J et al. NMR Biomed. 2002;15(7-8):543-552. [5] Arfanakis K et al. AJNR. 2002;23(5):794-802. [6] Salmond CH, et al. Neuroimage 2005; [7] Song et al. Neuroimage 2005; 15;26(1):132-140. [8] Hasan KM et al. JMIR 2005; 21:735-743. [9] Netsch T & van Muiswinkel A. IEEE-TME 2004;23(7):789-798.[10] Schmithorst et al. Radiology. 2002; 222(1):212-218. [11] Deutsch GK et al. Cortex. 2005;41(3):354-63. [12] McGraw P et al. Radiology. 2005;236(1):221-230.

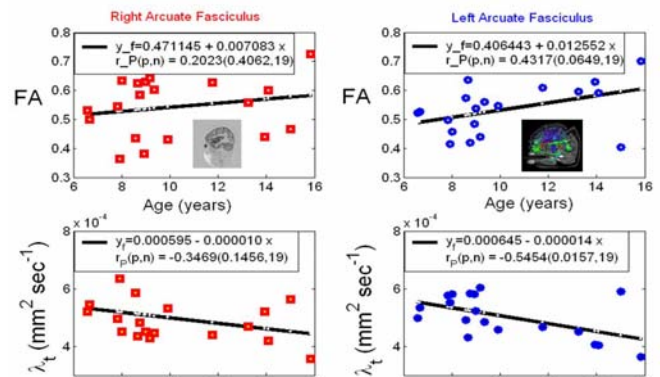


Figure 1. Variation of FA and transverse diffusivity with age in the right and left arcuate fasciculus in the healthy pediatric control group as an indicator of normal myelination. Notice the asymmetry of the age variation and the more specificity of the transverse diffusivity.

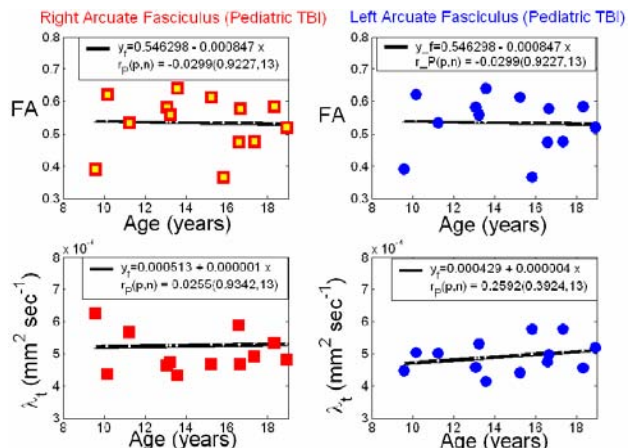


Figure 2. FA vs. age variation in the TBI group. Notice the bilateral lack of age related increase in FA and concomitant decrease in the transverse diffusivity which is indicative of impairment or arrested myelination.