

# In Vivo <sup>1</sup>H MRS Observation of Brain Succinate in a Subject With Cerebritis and Gram Positive Sepsis

D. J. Wang<sup>1</sup>, R. A. Zimmerman<sup>1</sup>

<sup>1</sup>Children's Hospital of Philadelphia, Philadelphia, PA, United States

## Abstract

Proton brain MRS studies was conducted on a 2-year old diagnosed with cerebral palsy, developmental delay, cerebritis and gram positive sepsis. 2D CSI <sup>1</sup>H MRS study on a T<sub>2</sub> hyperintense region in the left posterior frontal and parietal regions indicated significantly elevated levels of lactate, slightly elevated choline and decreased NAA. In addition, a large singlet peak was observed at 2.40 ppm in the spectra from the lesion. This appears to be that of the succinate, judging from its chemical shift and line shape. This metabolite was previously reported in *in vitro* and *in vivo* studies of brain abscess (1,2). In these studies, normal metabolites such as NAA, creatine and choline were absent, and acetate, succinate, amino acid and/or alanine were observed. In our subject, in addition to the strong succinate resonance, significant levels of the normal metabolites were detected and no acetate, alanine or amino acid was seen. In addition, our MRI data shows no evidence of frank intracranial abscess but a more diffuse cerebritis.

## Materials and methods

MRS/MRI studies were conducted on a Siemens Magnetom Vision 1.5T MR scanner with a circularly polarized head coil. Clinical T1 and T2 weighted, diffusion, and 3D TOF MRA of the circle of Willis images were conducted. Three-plane HASTE images were obtained to guide the positioning of the region of interest. 2D <sup>1</sup>H CSI spectroscopy through the level of centrum semiovale (Fig.1) was conducted in the axial plane in a 7 (A/P) x 7 (L/R) x 1.5 (S/I) cm<sup>3</sup> region, with point-resolved spectroscopy (PRESS) (3) localization technique. Spectral parameters were: TR = 1600 msec, TE = 135 msec, 16 x 16 phase encoding, two scan averages with a total acquisition time of 13.46 minutes. Prior to Fourier transform and phase correction the raw spectral data was multiplied with an exponential function corresponding to a 4 Hz line broadening. No baseline correction was performed.

## Results

MR exam revealed the largest lesion in the left posterior frontal and parietal lobes with lesser involvement of the right frontal lobe (Fig.1). Cortical necrosis in the left parietal lobe was also observed. Fig. 2 shows the 2D CSI spectral map from the left centrum semiovale region. Localized spectra shown in Fig.3 and 4 indicate significantly elevated levels of lactic acid, succinate and slightly decreased NAA and elevated choline in the lesion. Contralateral cingulate gyrus region shows decreased NAA and slightly elevated choline and lactate but no succinate (Fig. 5, 6). The line shape and chemical shift seems to indicate that resonance at 2.4 ppm is from that of succinate. The peak area ratios of the succinate to creatine, NAA to creatine and lactate to creatine are 0.95, 1.21 and 0.93, respectively for spectra extracted from the center of the lesion.

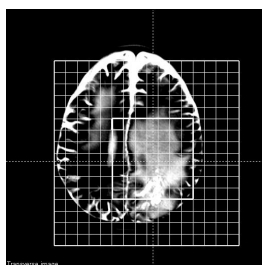


Figure 1.

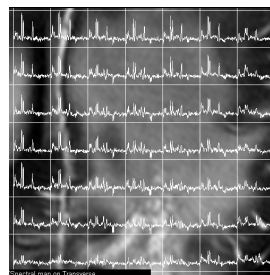


Figure 2.

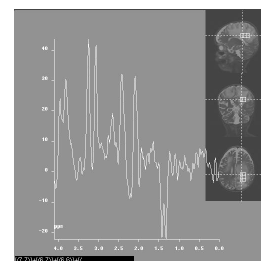


Figure 3.

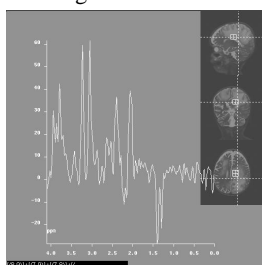


Figure 4.

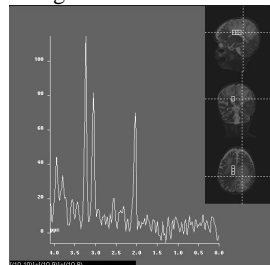


Figure 5.

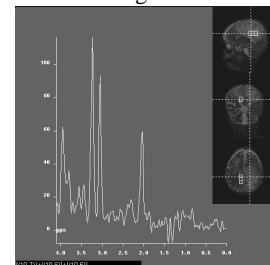


Figure 6.

## Discussion

In addition to succinate, several other metabolites such as pyruvate (4), glutamine and glutamate all are known to have resonance signal(s) in the vicinity and thus can contribute to this signal observed at 2.40 ppm in the MR spectrum. Although contribution from glutamine and glutamate (Glx) can not be ruled out completely, contamination from Glx should be small under the current study condition (TE=135 msec). In addition, this resonance line appeared to be a sharp single peak which is not compatible with the normal pattern of Glx which have a broad pattern of multiplet peaks due to extensive spin couplings. Pyruvate (2.38 ppm) is highly unlikely, as there is no evidence of enzymatic defects (5). The MR appears to be that of cerebritis, without frank intracranial abscess. Inflammatory demyelination can mimic cerebritis on MR, but the clinical setting strongly favors an infectious etiology. MRS data also favors cerebritis, with spectral patterns different from that previously reported in brain abscess.

## References

1. Remy C, Grand S, Lai S, et al. <sup>1</sup>H MRS of human brain abscesses in vivo and in vitro., *Magnetic Resonance in Medicine*. 34(4):508-14, 1995
2. Akutsu H, Matsumura A, et al. Chronological change of brain abscess in <sup>1</sup>H magnetic resonance spectroscopy, *Neuroradiology*, 2002; 44:574-578.
3. Bottomley PA, Spatial localization in NMR spectroscopy in vivo. *Ann NY Acad Sci* 1987;508:333-348
4. Wang D., Simon E., et al., *In vivo* <sup>1</sup>H MRS observation of brain pyruvate in a neonate with pyruvate dehydrogenase deficiency, *ISMRM* 2546, 2002
5. Brown GK, Otero J. Pyruvate dehydrogenase deficiency. *J Med Genetics*, 1994; Nov 21(11): 875-9